

# When is it Time to Consider Facial Reanimation after Acoustic Neuroma Surgery

Babak Azizzadeh, MD, FACS

Director – Facial Paralysis Institute  
Beverly Hills, CA

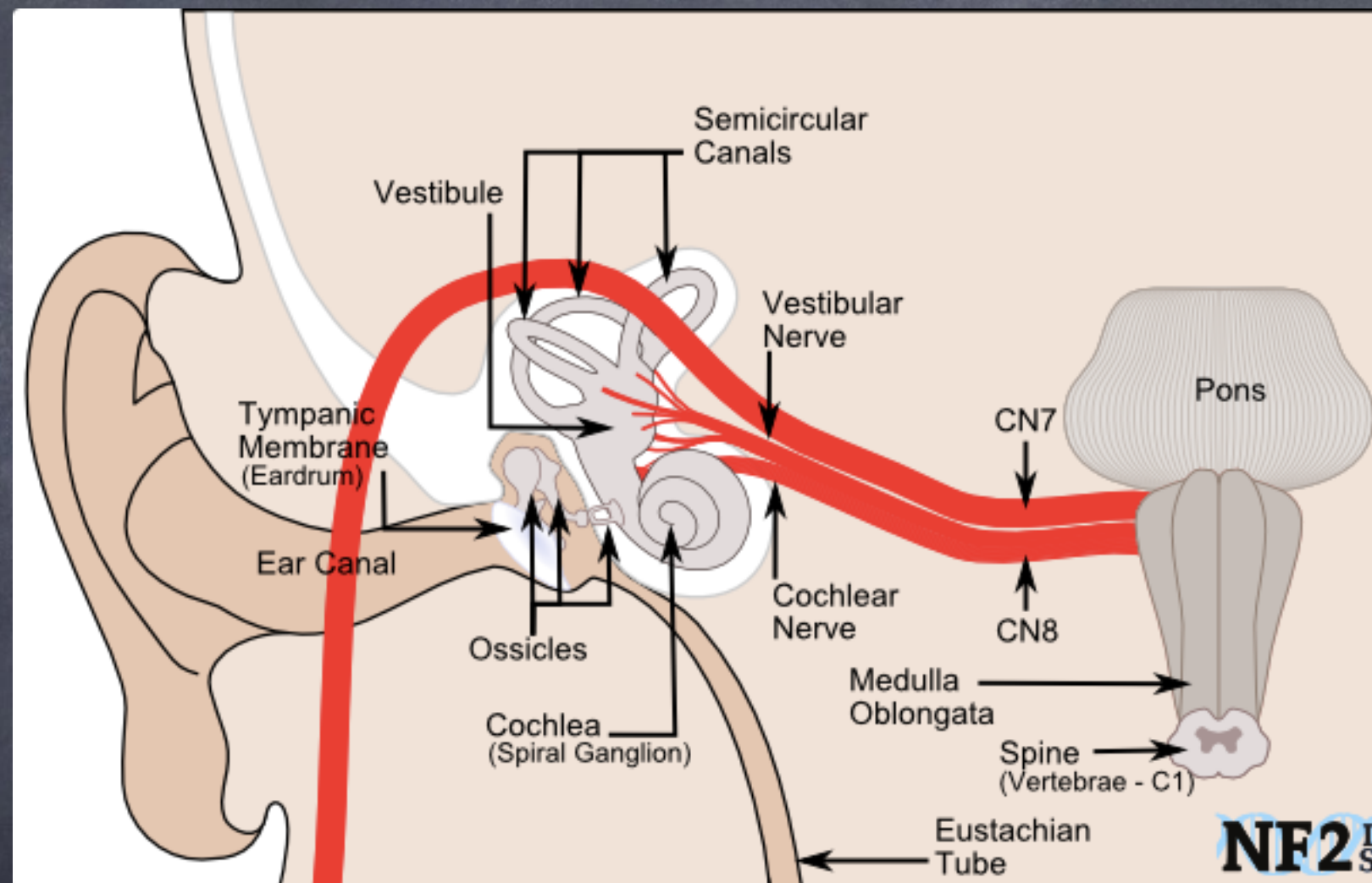
Attending Surgeon, Cedars-Sinai Medical Center  
Associate Clinical Professor of Surgery, UCLA  
Co-Director, USC Facial Plastic Surgery Fellowship Program



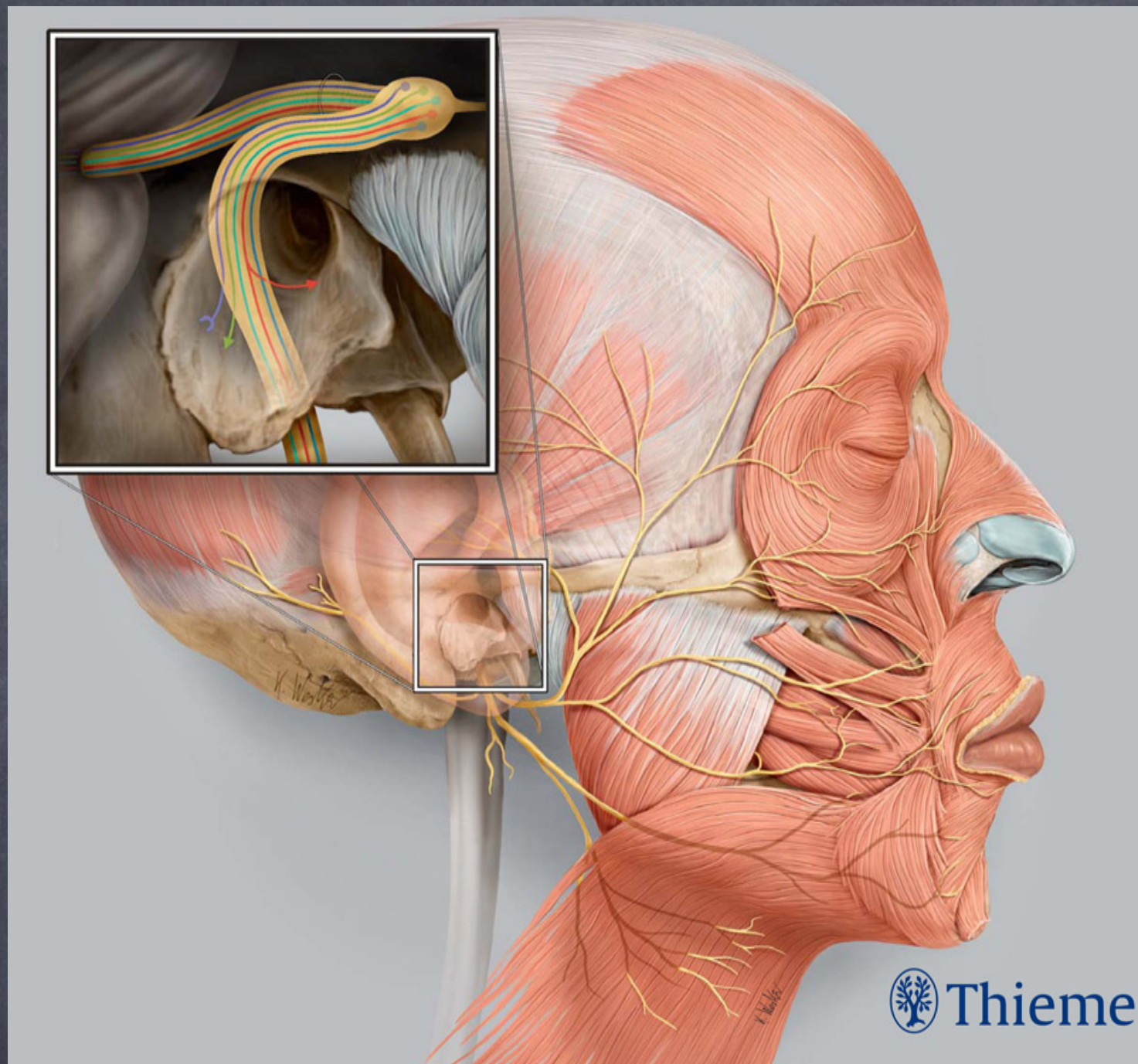
- Static Sling procedures, temporalis muscle transfer and hypoglossal-facial nerve transfer have been the mainstay of treatment for facial paralysis
- In this webinar, I will outline:
  - Anatomy of facial nerve and muscles
  - My current evolution in facial reanimation techniques and concepts in patients who have developed paralysis following acoustic neuroma surgery
  - Discuss the timing of surgery following acoustic neuroma treatments
  - Discuss combination treatments in order to achieve optimal outcome
  - Overview surgical techniques to address synkinesis and partial paralysis
  - Note: majority of patients in this presentation have undergone eyelid and brow reconstruction
  - Note: Neuromuscular retraining/physiotherapy and botox are important adjuncts to treatments that will not be discussed in this presentation



# Facial Nerve Anatomy







Facial Nerve. Slattery, Azizzadeh  
(editors); Thieme; Jan 2014.

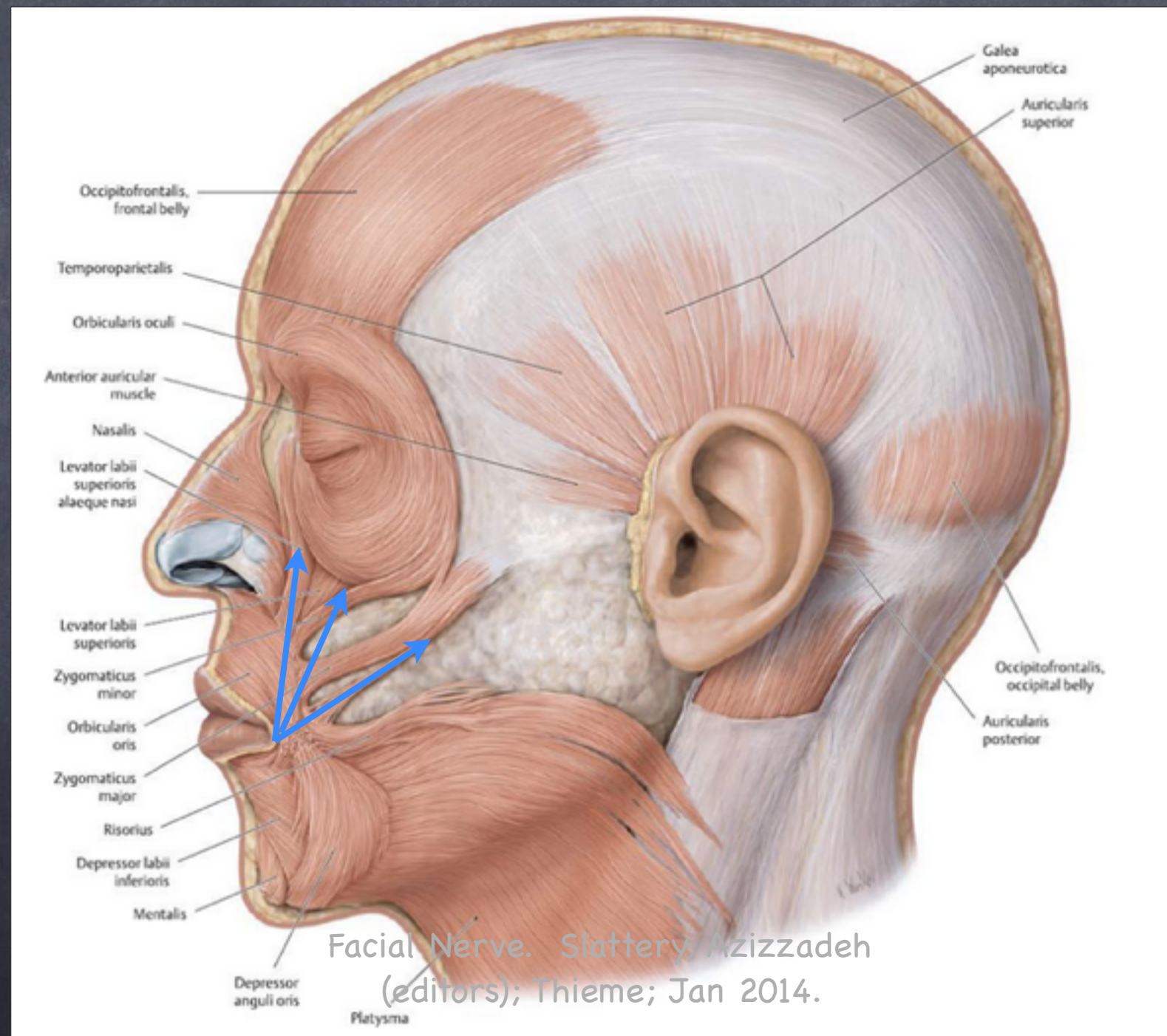


# Facial Nerve Function

- Muscles of facial expression
- Taste fibers to front of the tongue
- Tear gland & salivary gland secretions

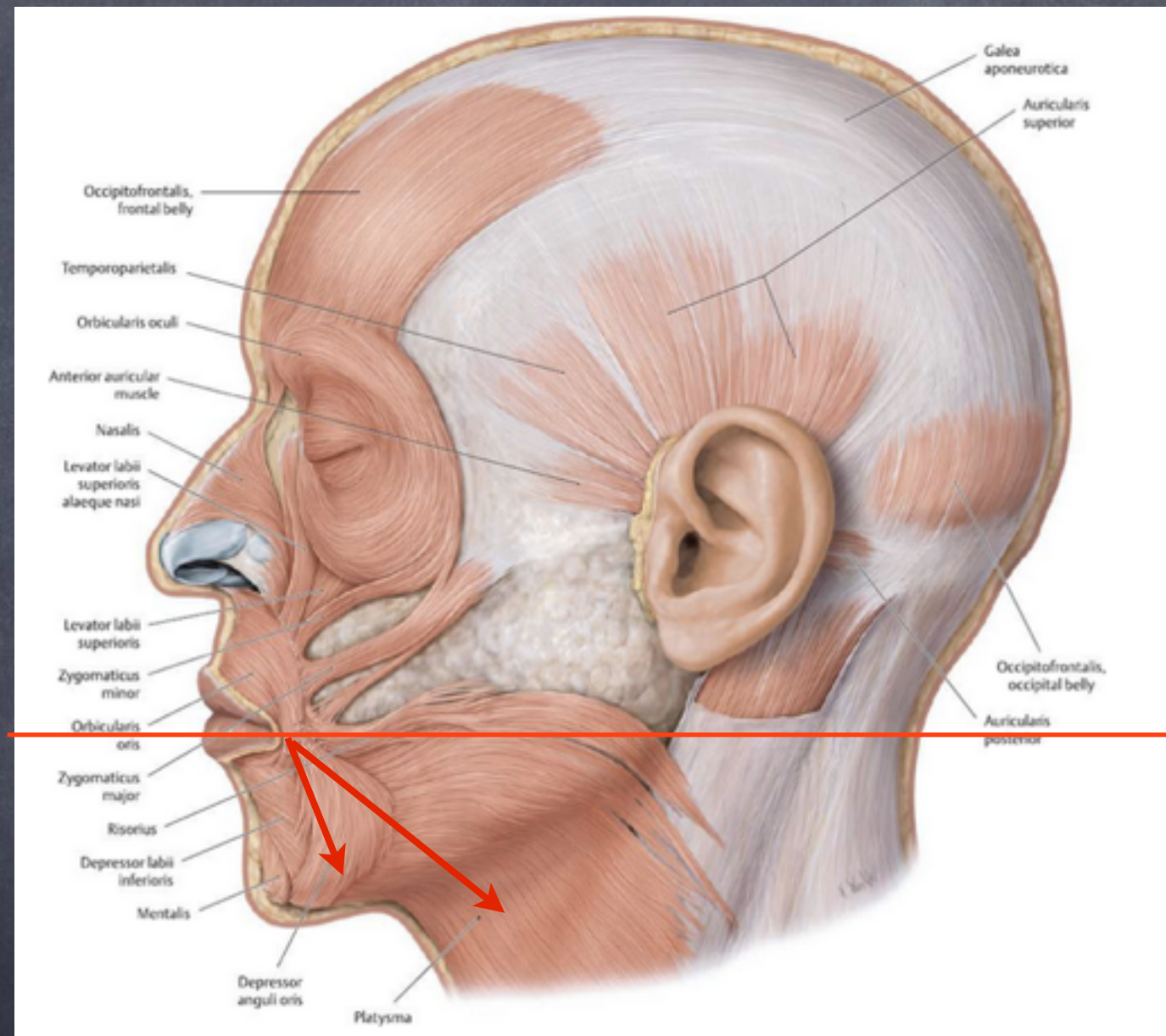


# Primary Smile Muscles: Zygomatic major & minor Levator Labii Alaeque Nasi





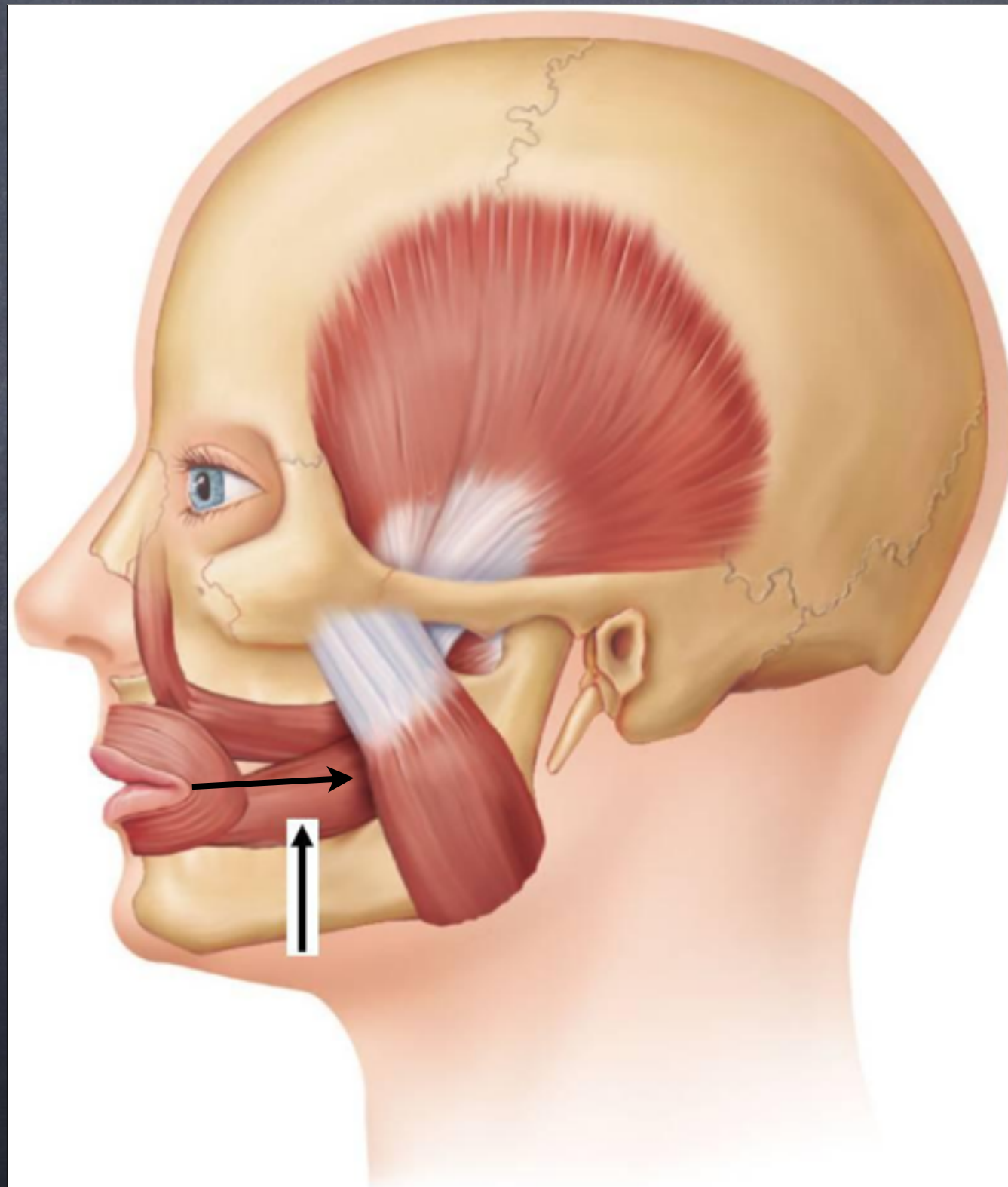
# Frowning Muscles: Platysma & DAO



Facial Nerve. Slattery, Azizzadeh  
(editors); Thieme; Jan 2014.



Buccinator:  
Holds the cheek to the teeth and  
assists with chewing





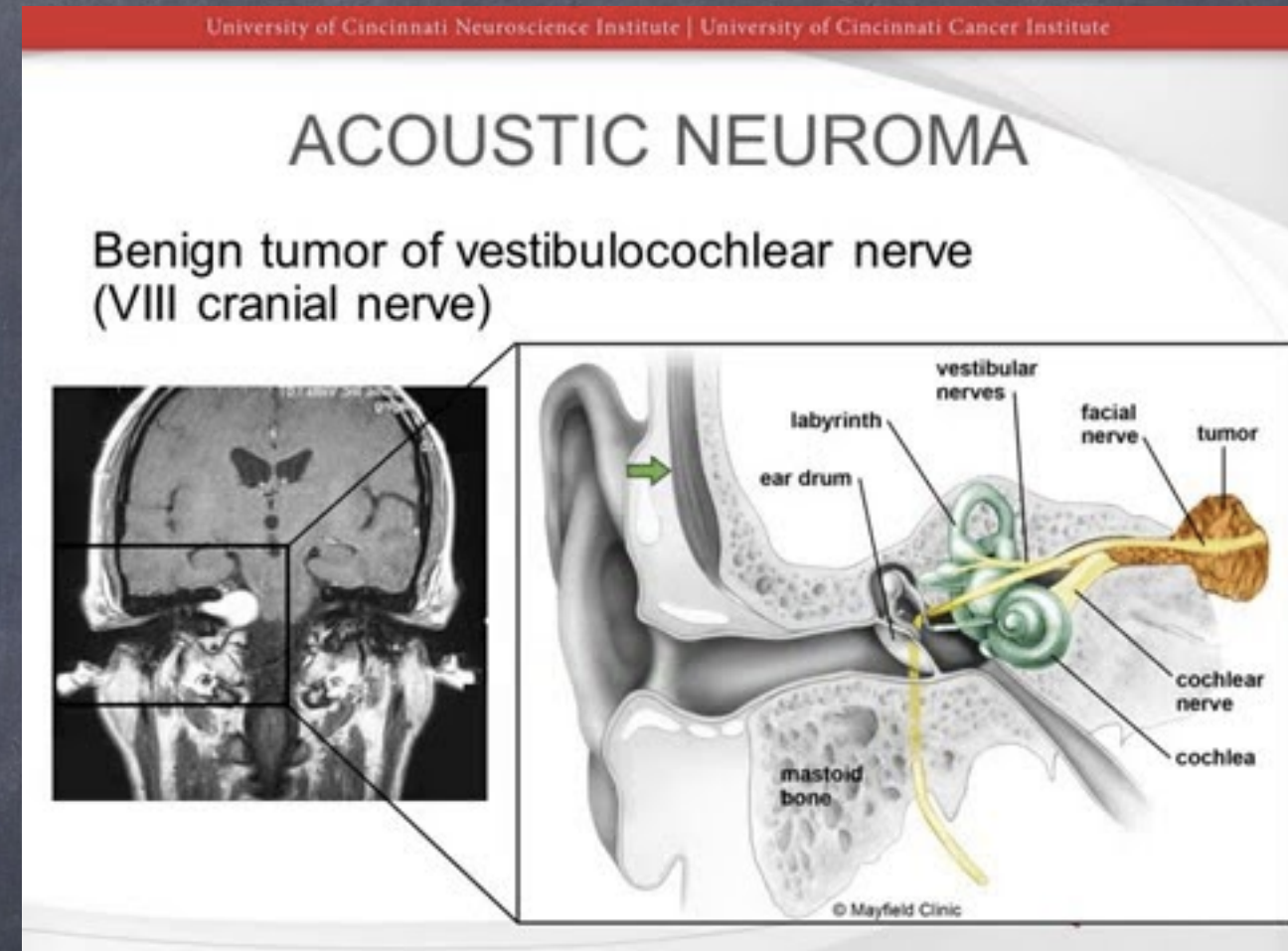
# Causes of Facial Paralysis

- Infectious: Herpes Simplex Virus (Bell's palsy), Zoster, Lyme, other
- Tumors: Acoustic neuroma, facial neuroma, parotid malignancies, cholesteatoma, metastasis
- Congenital: Mobius, CULP, hemifacial microsomia
- Traumatic: T-bone fx, iatrogenic, laceration, birth
- Neurologic: Central (upper division spared), other



# Acoustic Neuroma

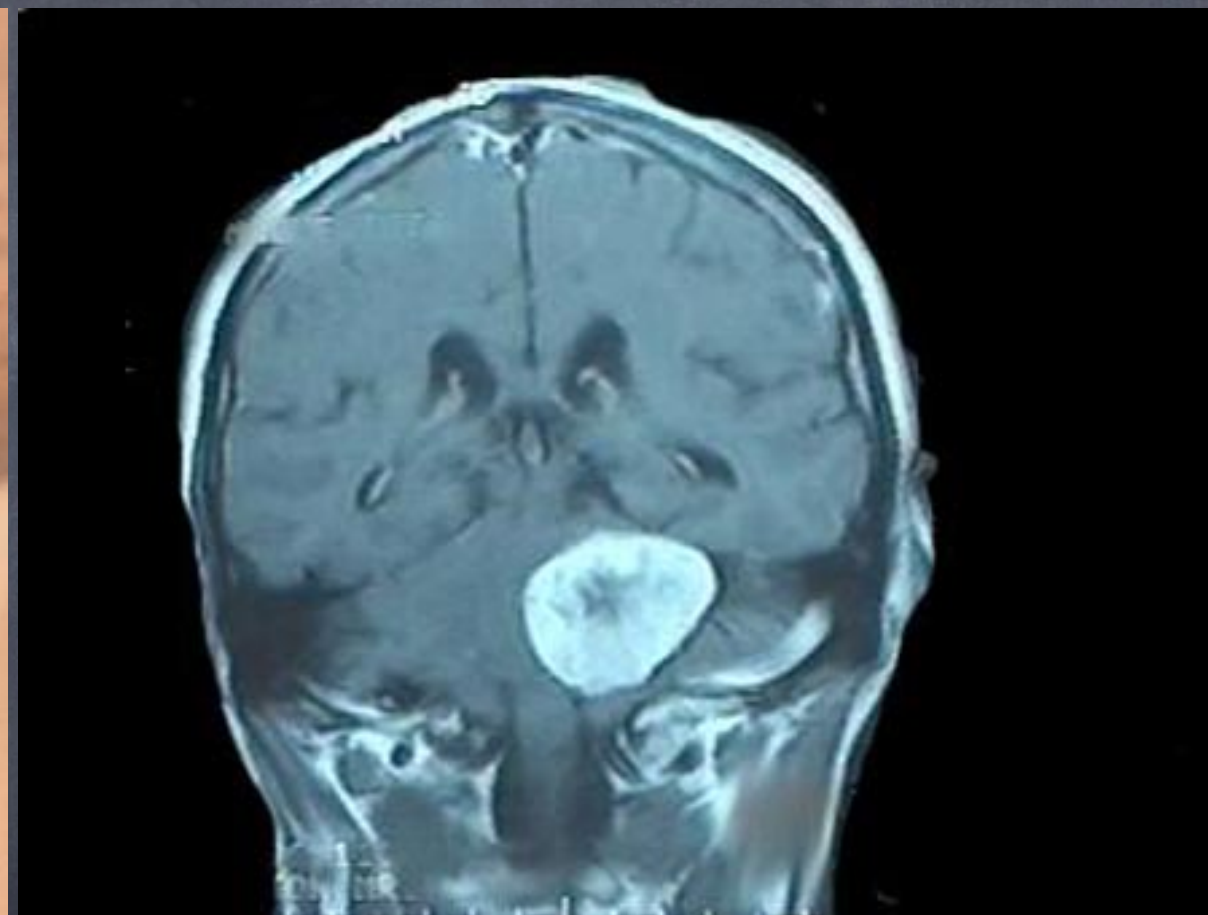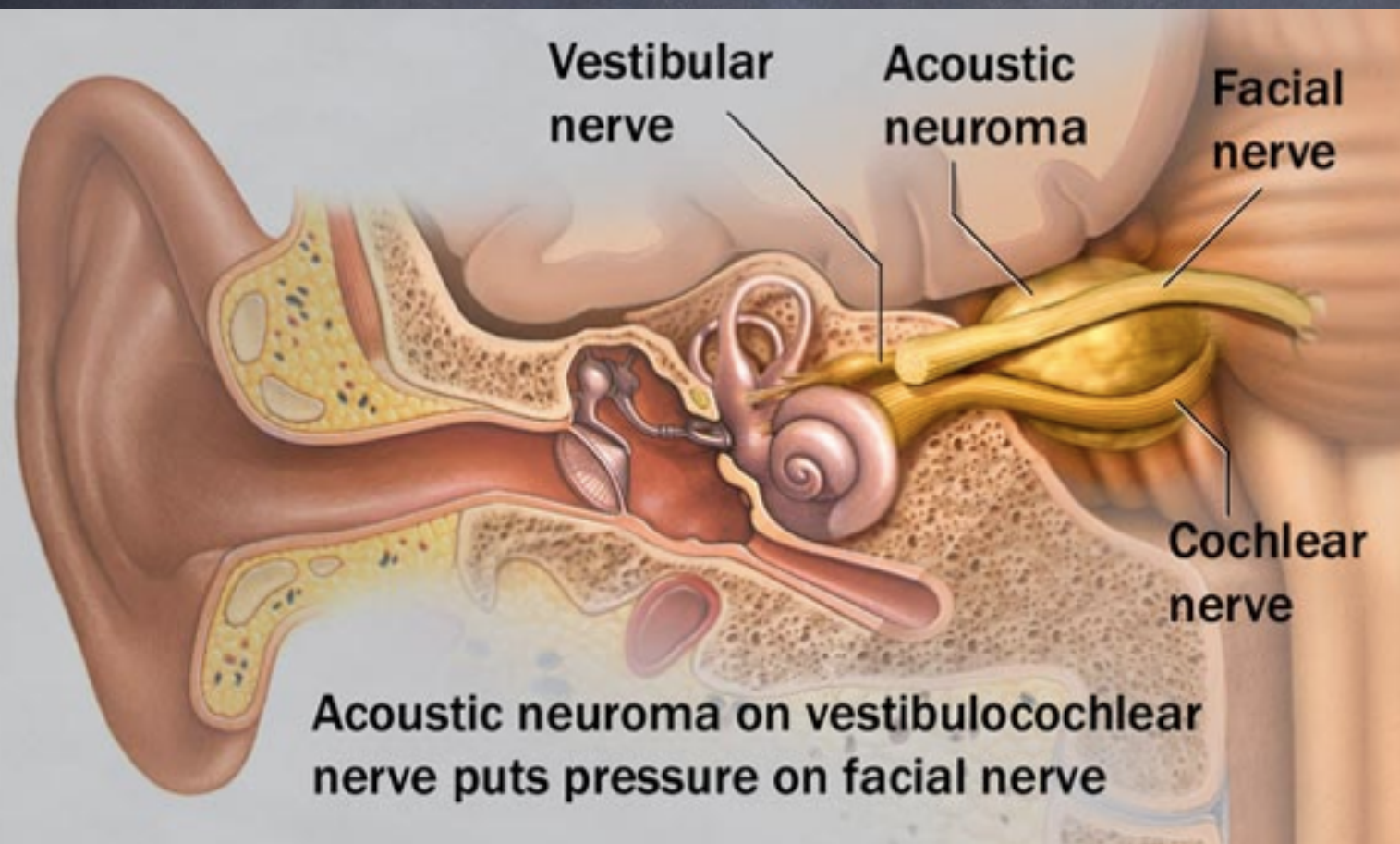
- Cerebellopontine angle (CPA): Intracranial extra-axial
- Schwann cell sheath – Cranial Nerve VIII
- vestibular > cochlear nerve
- AN account for 80% of all CPA tumors (20% are principally meningiomas)
- 0.7–1.0 people per 100,000
- NF2 --> Bilateral AN



[mayfieldclinic.com](http://mayfieldclinic.com)



Growth is often slow; Facial nerve can usually accommodate the stretching without clinical symptoms (5-10%)



[www.braintumors.in/acoustic\\_neuroma](http://www.braintumors.in/acoustic_neuroma)

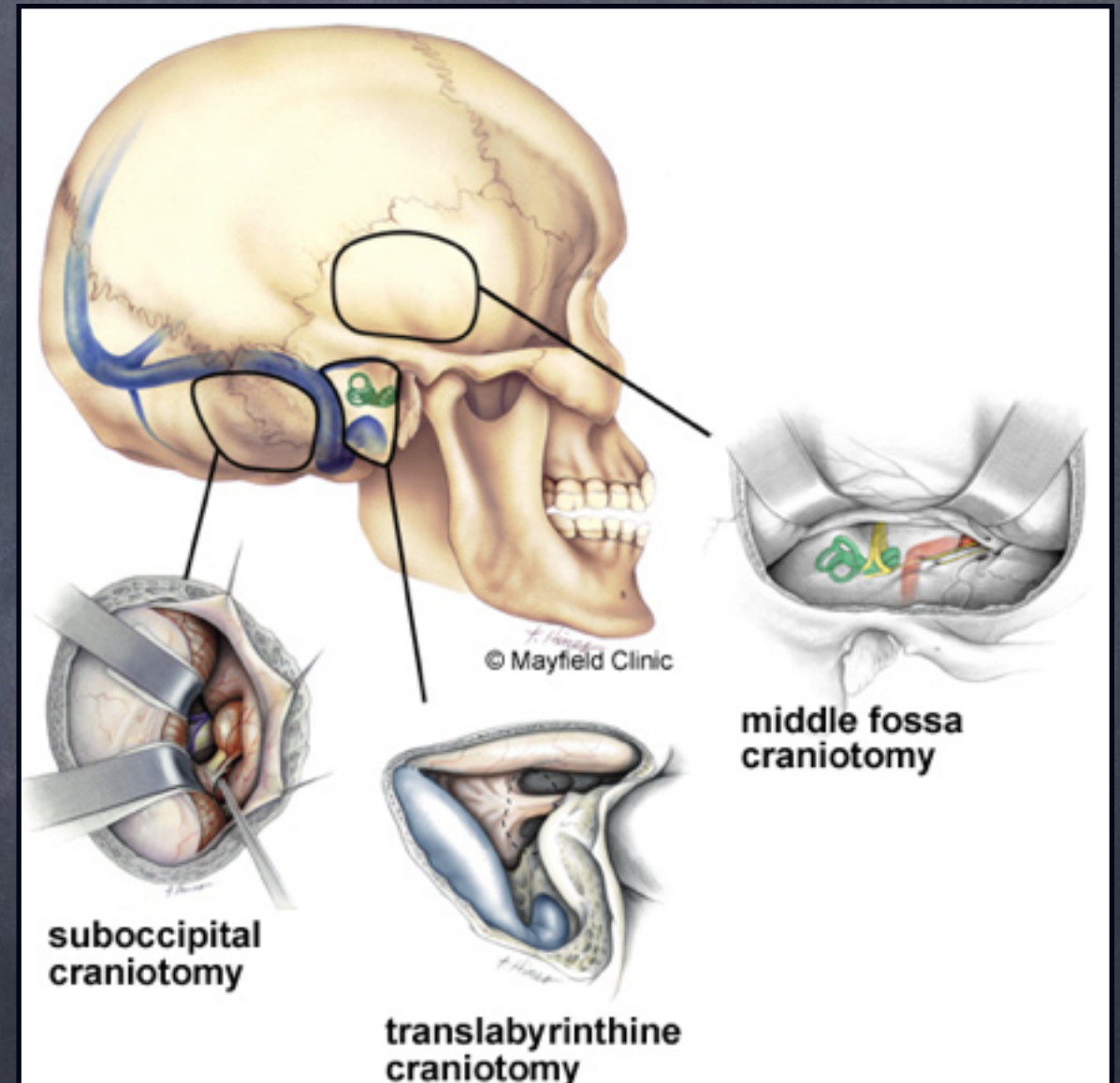


# Surgical Approaches

Retrosigmoid/suboccipital

Translabyrinthine

Middle Cranial Fossa



[mayfieldclinic.com](http://mayfieldclinic.com)



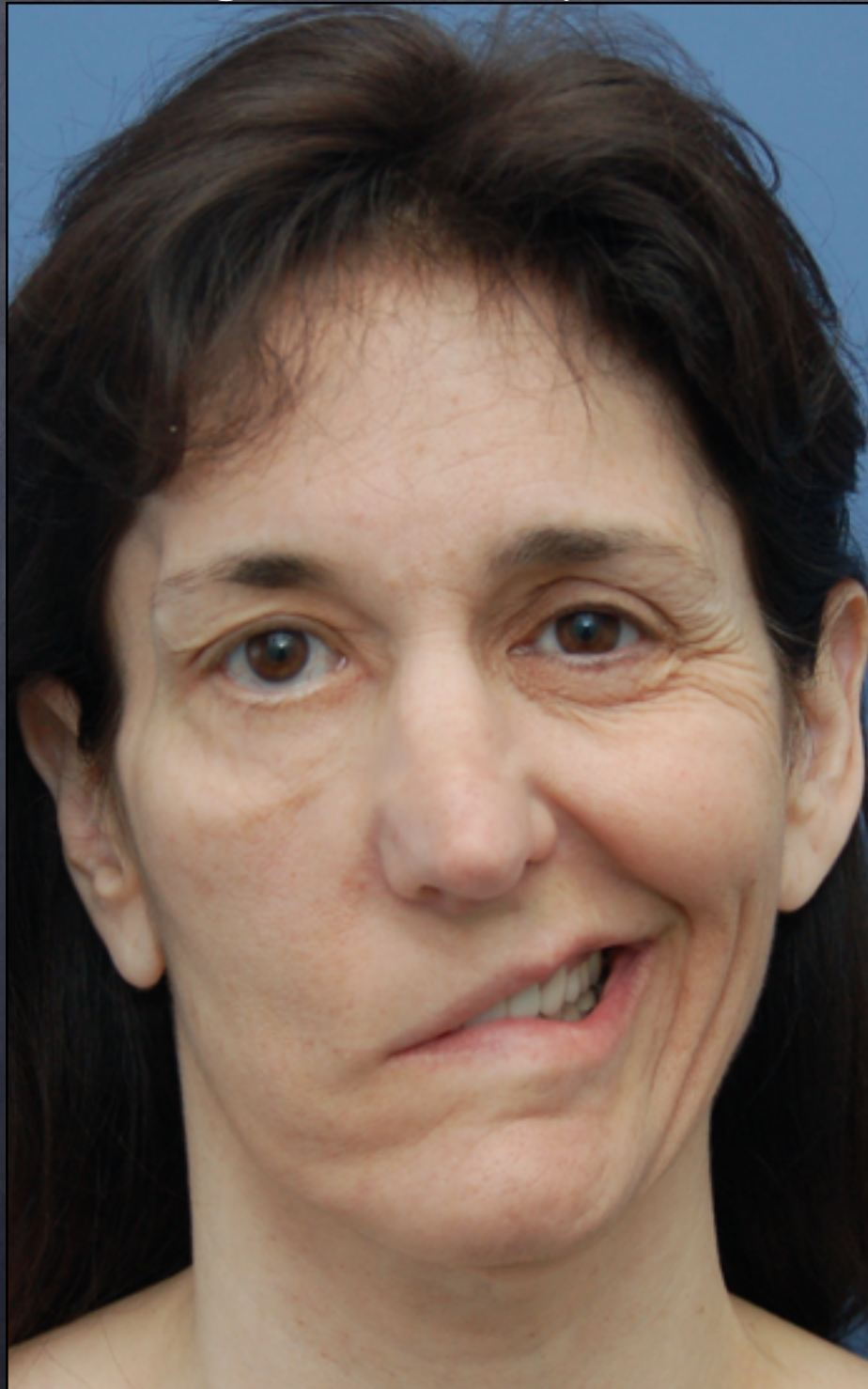# Facial Paralysis Types

- Complete
- Partial with synkinesis (most common)
- Partial without synkinesis
- Bilateral
- Congenital unilateral lower lip palsy (CULLP)

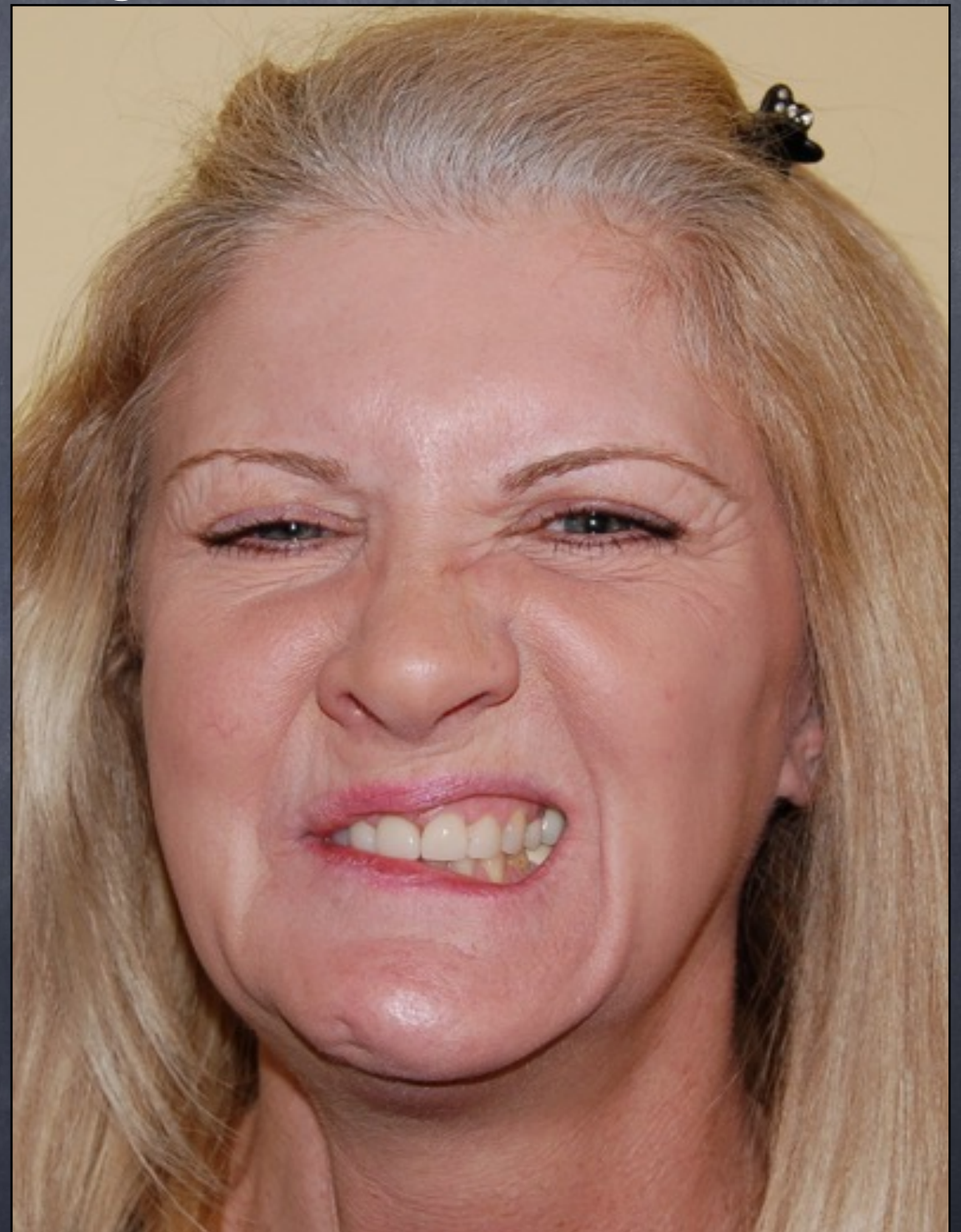

# Types of Facial Paralysis

Right Complete



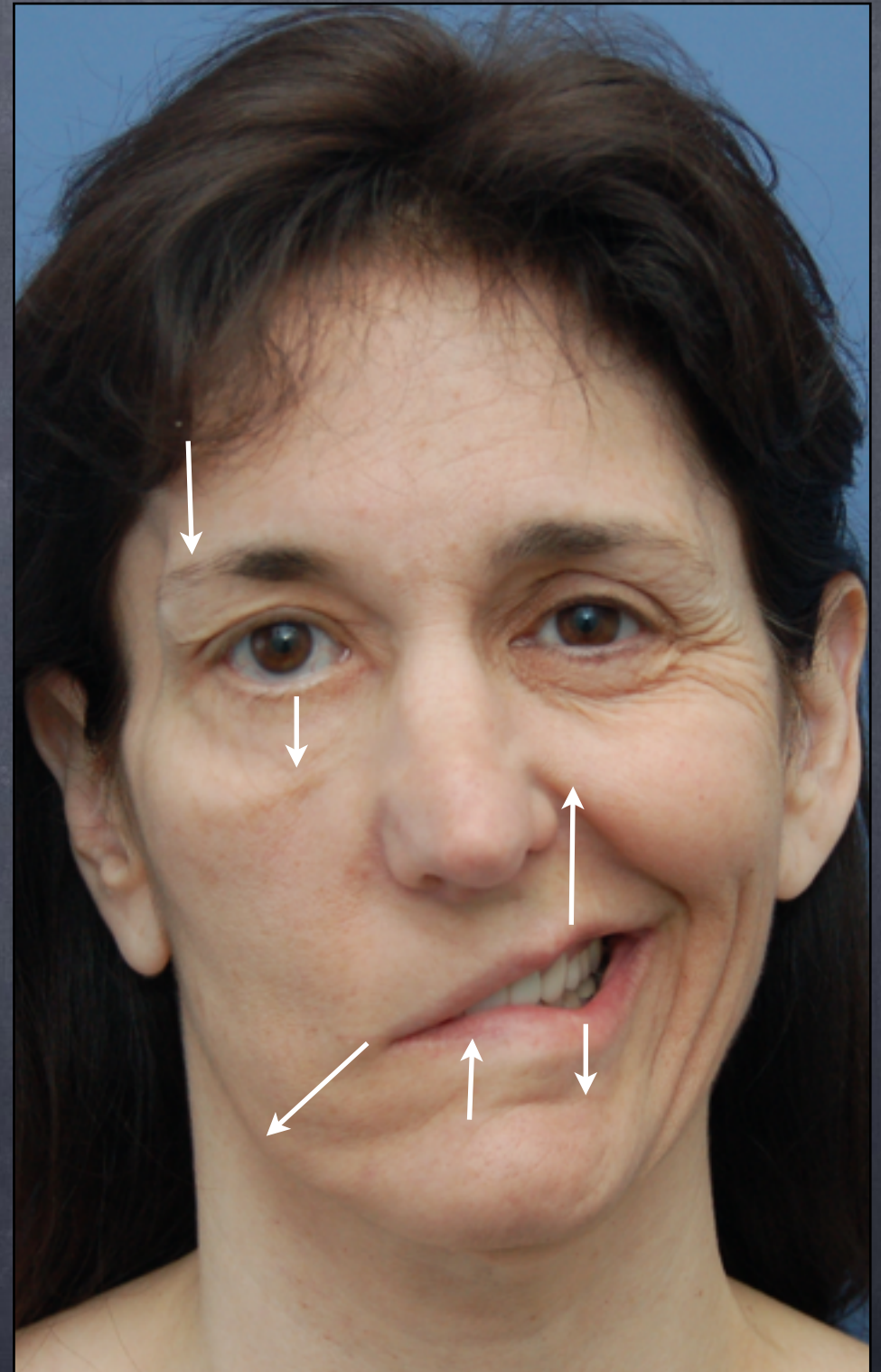
Right Partial/Synkinesis





# *Complete Facial Paralysis*

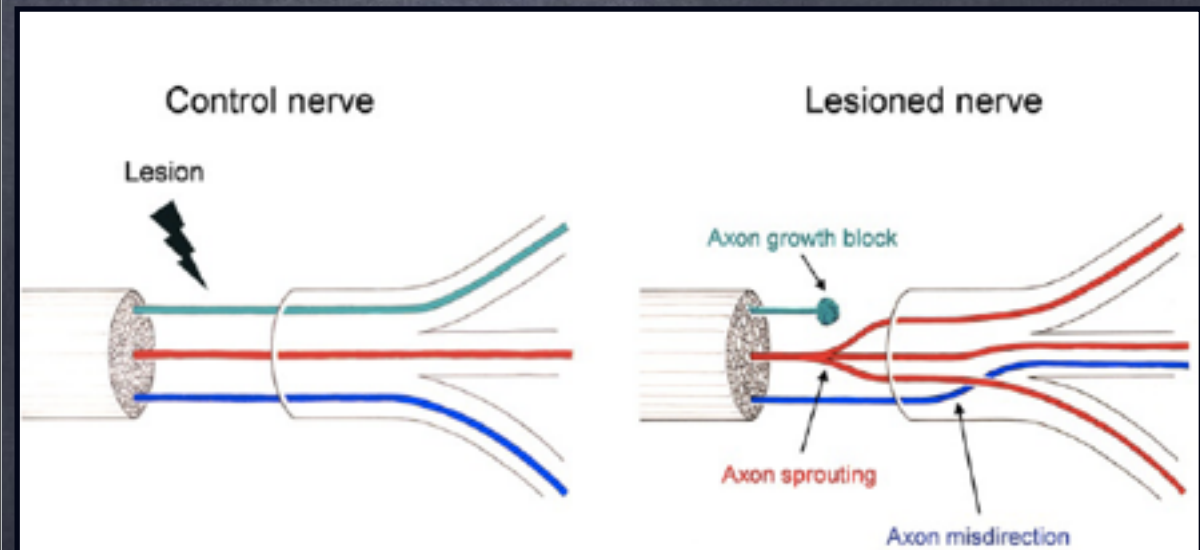
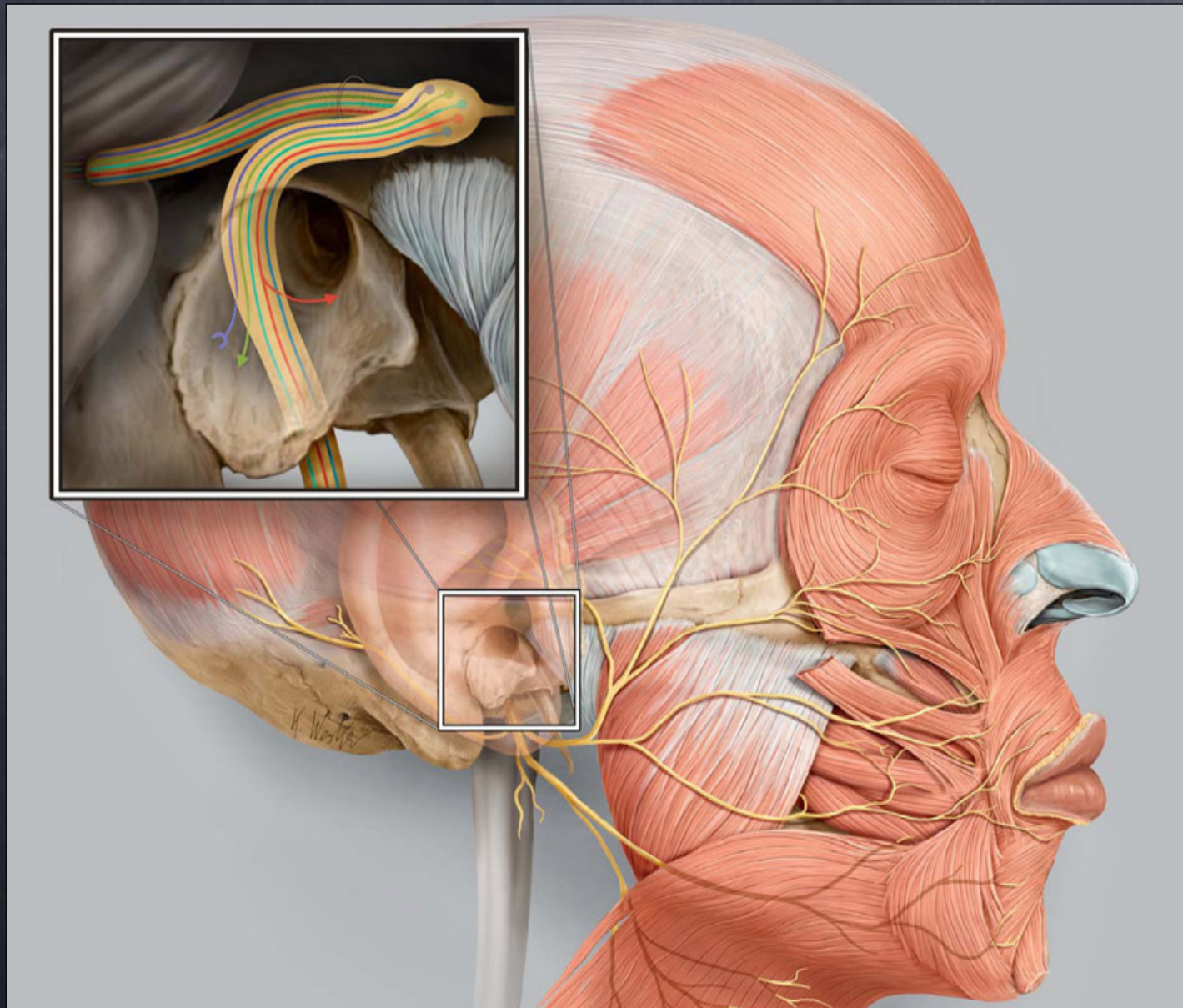
- Irreversible facial nerve injury
- Complete smile dysfunction
- Inability to close eyes; brow drooping; lower eyelid drooping
- Facial asymmetry of brows and face, atrophy of muscles and fat; Premature aging on affected side; lack of laugh lines
- Collapse of nasal valve leading to breathing issues
- Articulation difficulties, fluid escape from mouth, biting of lips and gums



Babak Azizzadeh, MD, FACS

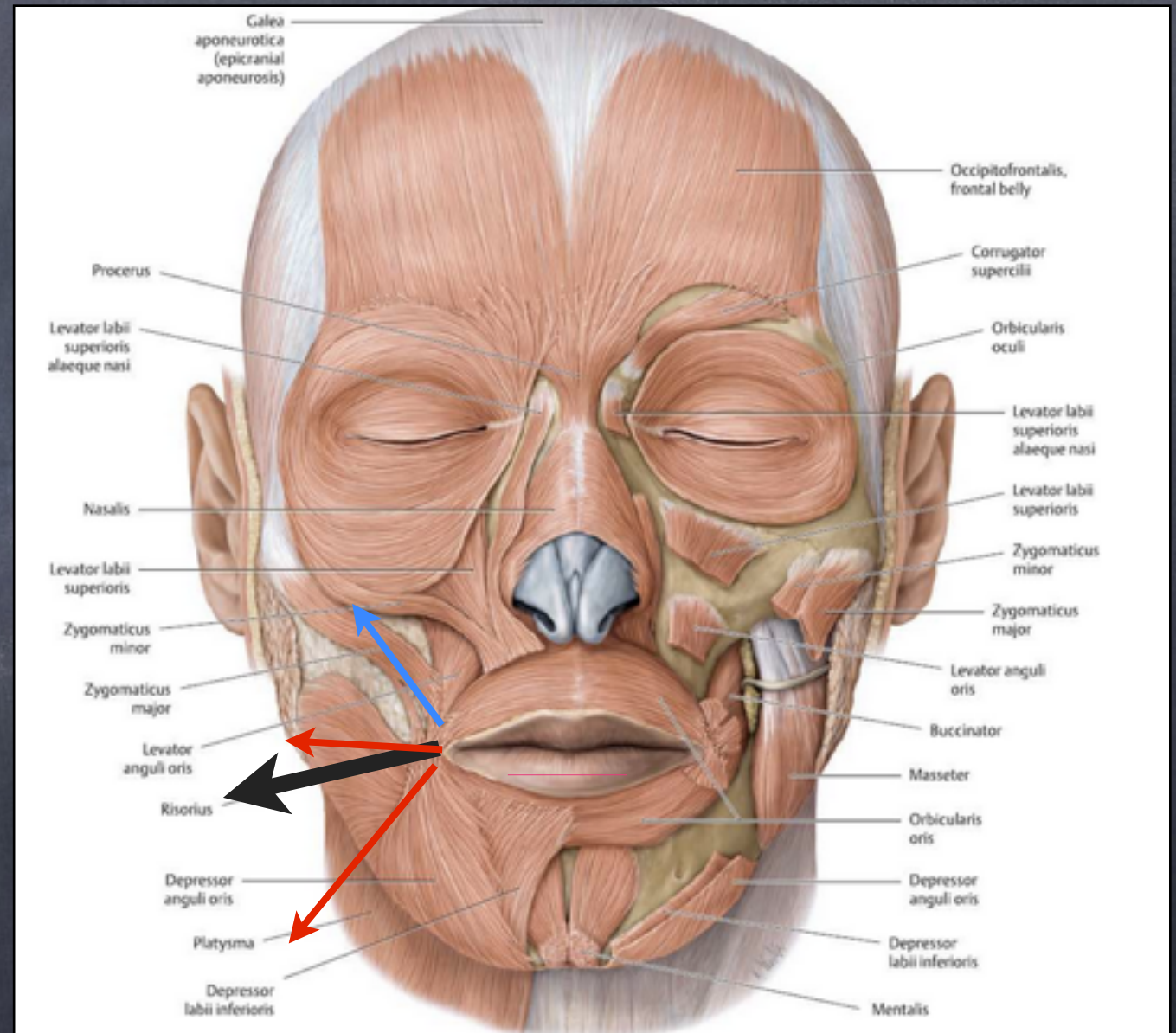
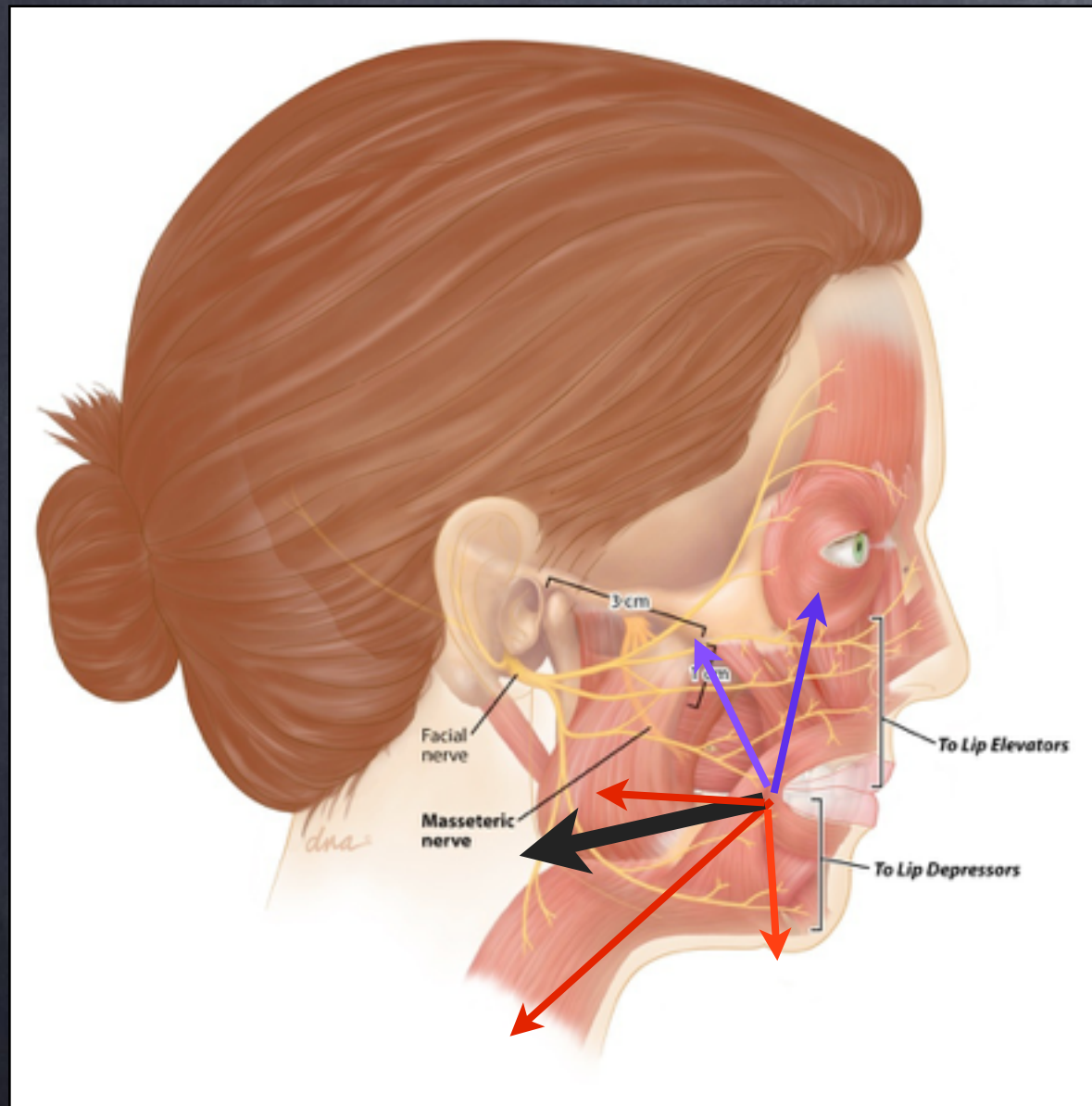


Any Form of Nerve Repair or Regrowth after an injury can Lead to misdirection of the nerves leading to “Aberrant Regeneration” or “SYNKINESIS”



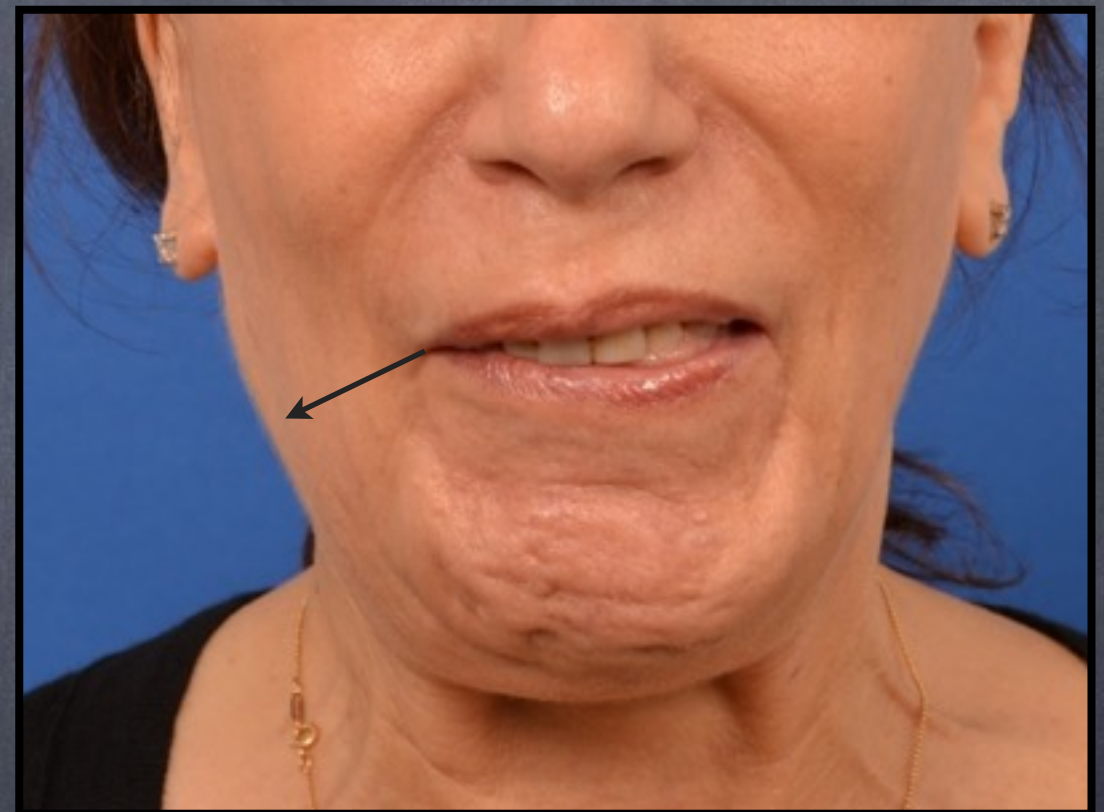
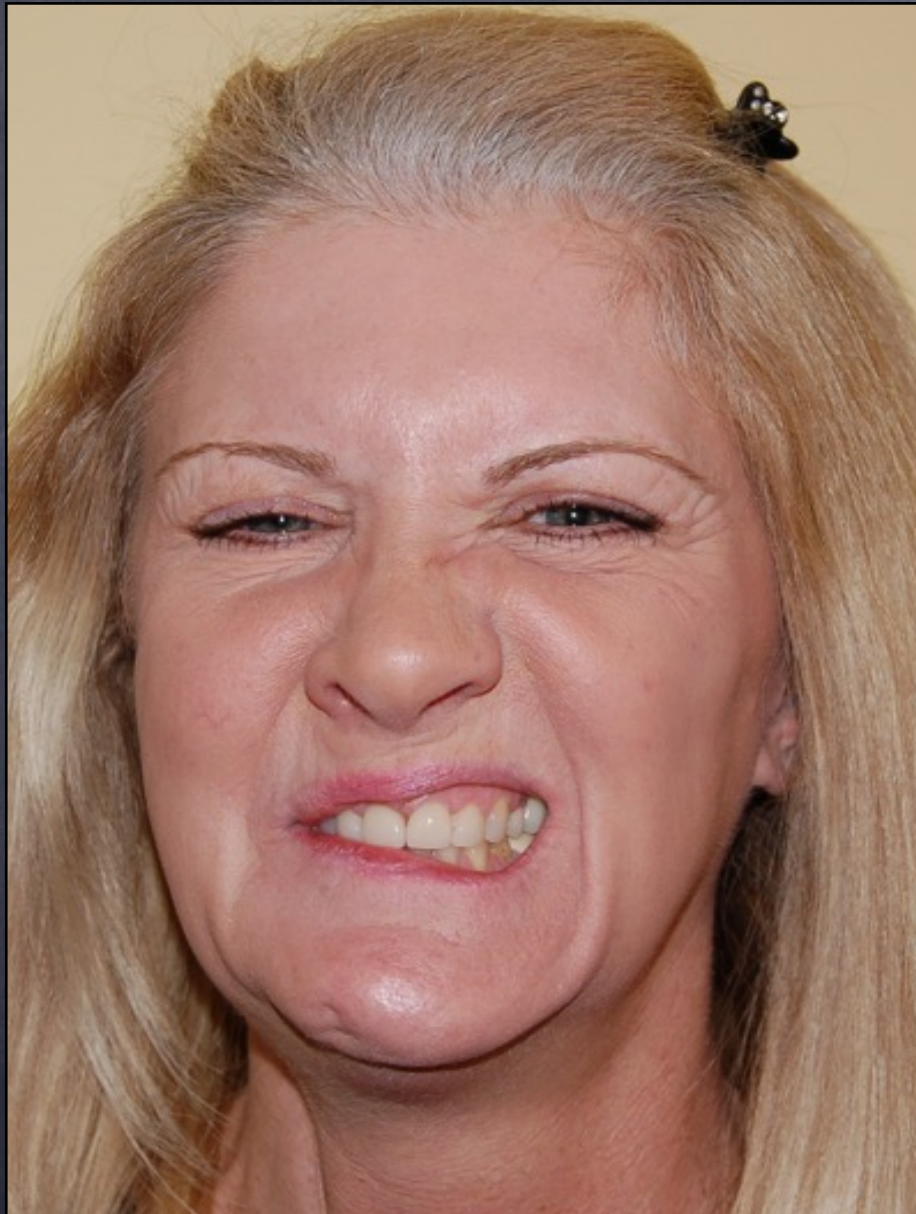
# SMILING, FROWNING & BUCCINATOR MUSCLES WORKING SIMULTANEOUSLY LEADS TO A FROZEN OR FROWNING SMILE





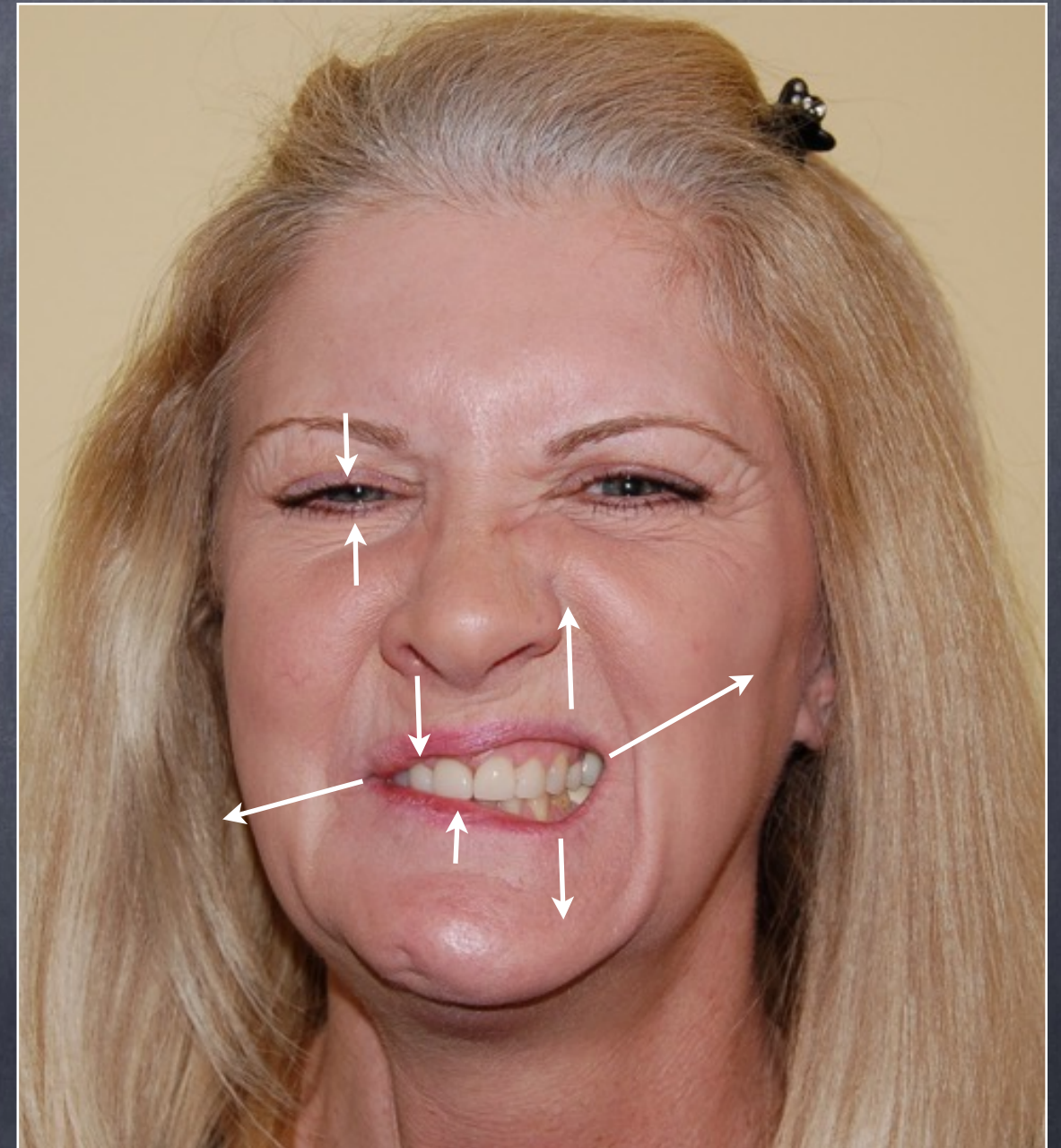
# Synkinesis Results in Uncoordinated and Simultaneous Facial & Eyelid Movement Mechanism





# *Partial Paralysis with Synkinesis*

- **REVERSIBLE** facial nerve injury, cranial nerve substitution (12-7), nerve repair
- Simultaneous and uncoordinated elevator and frowning activity (synkinesis)
- Eye closure variable, eyes narrow with smiling
- Tightness and increased facial tone --> deep nasolabial fold & slower aging process on affected side
- Typically brow elevation and movement of lower lip is limited
- Hyperactive mentalis (peau d'orange) and platysma



Babak Azizzadeh, MD, FACS



# Facial Reanimation

Facial nerve reconstruction is NOT PERFECT  
and cannot truly reproduce a perfect smile

However, we have significantly improved  
outcomes over the past decade



# Facial Paralysis Treatment

- Static – improves symmetry at rest without any improvement in smile
- Dynamic Voluntary – conscious smile mechanism (biting down, tongue-thrusting, etc.)
- Dynamic Spontaneous – unconscious smile mechanism; emotive conversation



# Facial Reanimation Goals

- Improve Dynamic Smile mechanism
- Enhance natural facial movement while communicating
- Improve speech articulation, drooling, biting of gums, and nasal obstruction
- Prevent eye complications
- Reduce tension and tightness
- Create symmetry of the face, eyes, and brows
- Improve self confidence and ability to socialize



# Evaluation & Treatment

- Immediate onset – Acute
- Long-standing – Chronic (>12 mo)



# Immediate-onset Facial Paralysis: Management

If no known cause is evident: Complete evaluation to rule out neoplasm; history, neurologic, ear evaluation; +/- imaging

Eye care: ointment, artificial tears, tape eyes shut at night, ophthalmology evaluation, surgical if eye health is in serious danger



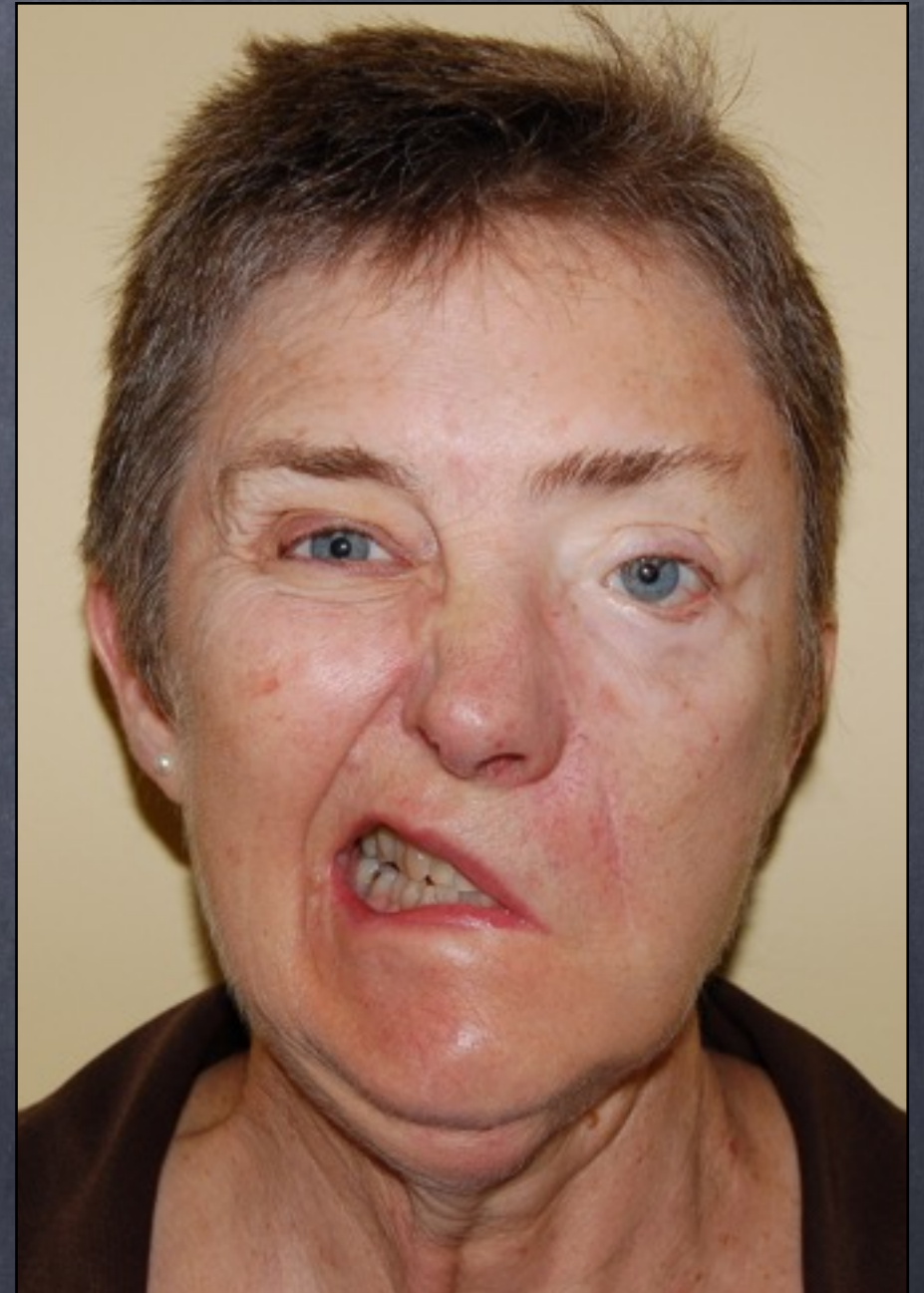
# Immediate-onset Facial Paralysis: Management

- Acoustic Neuroma
  - Intra-op: nerve graft if possible
  - post-op: dependent on status of nerve during surgery
  - **DO NOT WAIT OVER 18 MONTHS IF NERVE COMPLETELY PARALYZED**



# Long-standing Facial Paralysis: Management

- make sure there is no evidence of tumor or recurrence
- Treatment typically initiated after one year
- If nerve definitely sacrificed then consider early reconstruction





# Personal Philosophy for Facial Reanimation Following Acoustic Neuroma Surgery



# Irreversible Complete Facial Paralysis

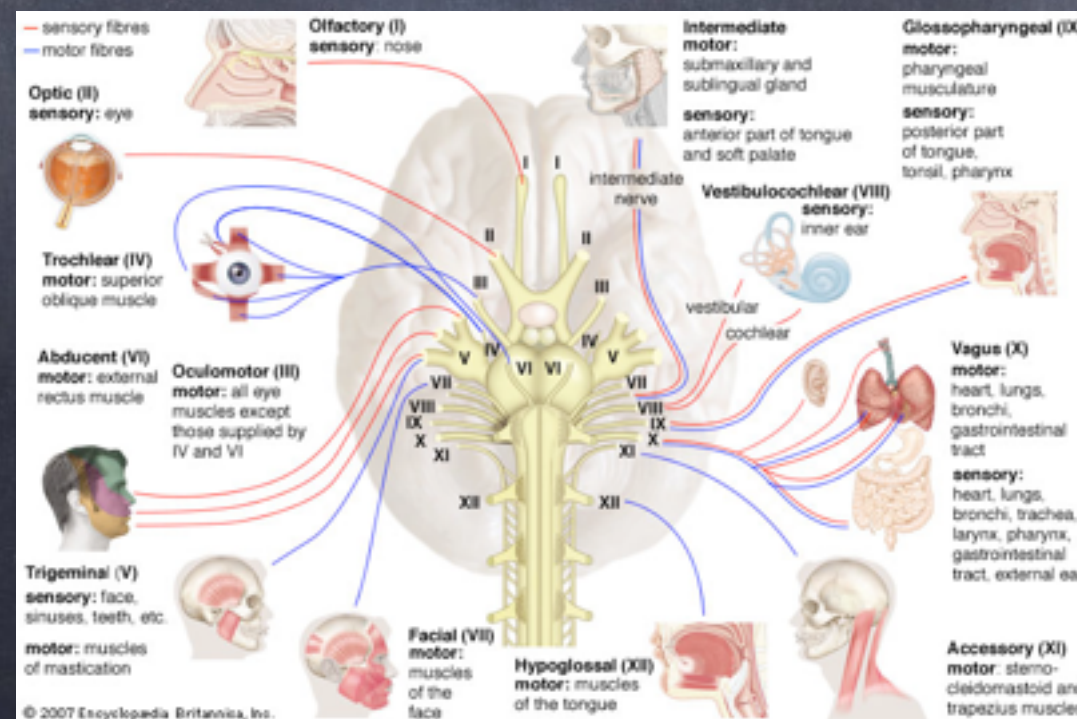


- Ophthalmic care as needed depending on severity condition
- Once determined the condition is irreversible (within 18-24 months or earlier) proceed with two stage operation to improve facial tone and provide smile mechanism
- stage 1: masseteric-facial nerve transfer with simultaneous cross facial nerve graft
- stage 2: gracilis free flap
- NMR, botox, fillers, face/neck lift to optimize outcome
- Patients with >24 months then proceed only with cross face nerve graft and gracilis muscle tx
- Other options, orthodromic temporalis tendon transfer, hypoglossal facial nerve transfer, gracilis flap innervated by masseteric nerve



# Nerve Substitution Techniques

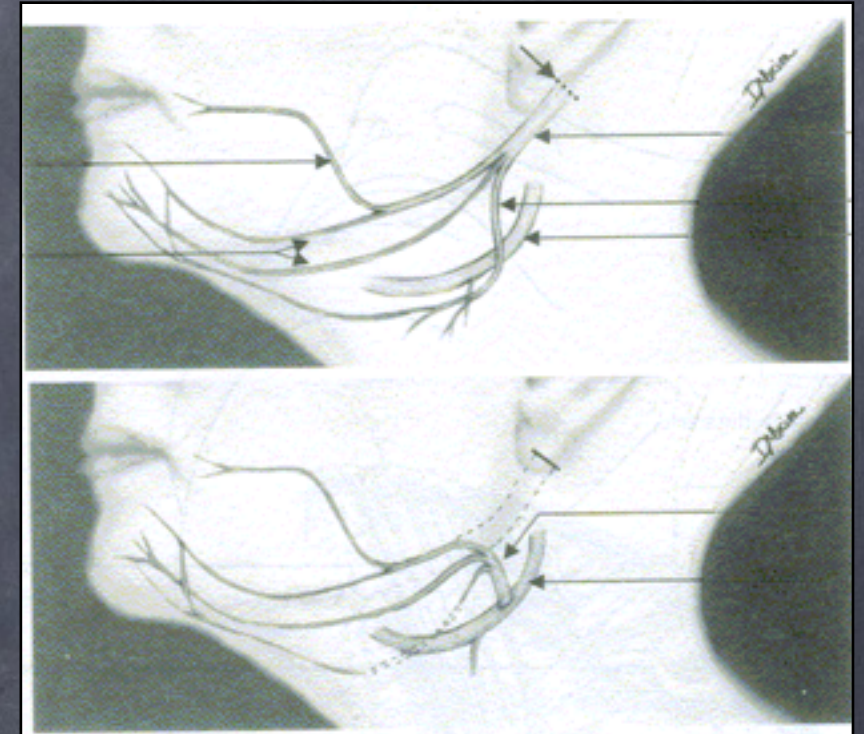
- Over the past century, several cranial motor nerves have been used for facial reanimation including the spinal accessory (XI), contralateral facial (VII), and hypoglossal nerves (XII).
- Hypoglossal nerve is the most commonly used





# Hypoglossal-Facial Nerve Transfer (12-7 Transfer)

- Uses the nerve that controls tongue movement (hypoglossal nerve) to give nerve input into a non-functioning facial nerve & muscles
- Creates resting muscle tone & “moves” the face with tongue thrusting
- The facial nerve and all the facial muscles must be available

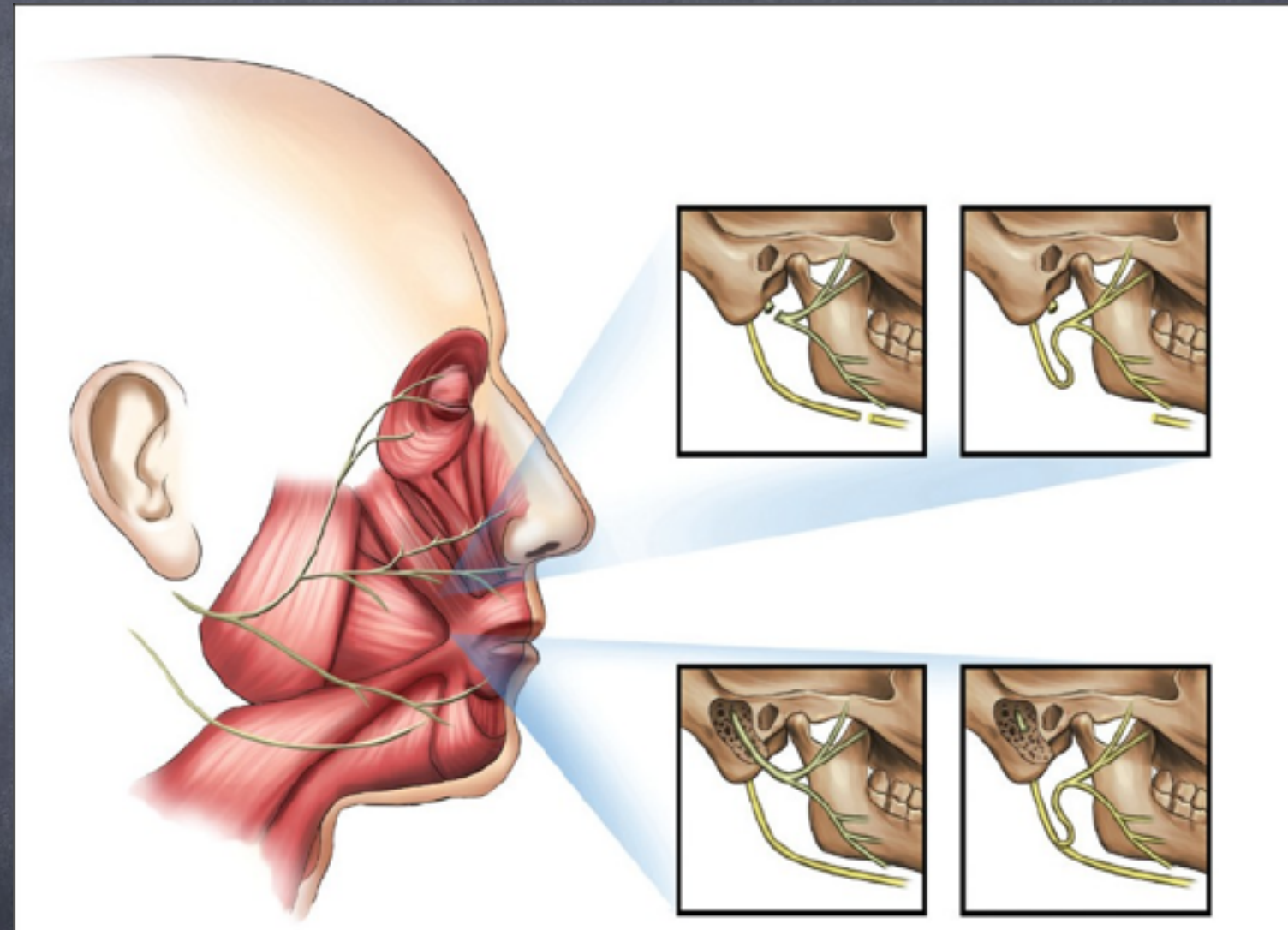


The “Babysitter” Procedure: Minihypoglossal to Facial Nerve Transfer and Cross-Facial Nerve Grafting. Julia K. Terzis; Kallirroi Tzafetta. Plastic and Reconstructive Surgery 2009 Vol: 123:865-876. DOI: 10.1097/PRS.0b013e31819ba4bb



# Hypoglossal-Facial Nerve Transfer

- Avoid using this method: multiple cranial nerve involvement; NF2; Adenoid cystic; partial FNP
- My practice: Often combined with CFNG/ gracilis flap which helps achieve spontaneous smile mechanism



Surg Neurol Int 2012, 3:46

Bell's palsy and partial hypoglossal to facial nerve transfer: Case presentation and literature review

Mariano Socolovsky<sup>1</sup>, Miguel Domínguez Páez<sup>2</sup>, Gilda Di Masi<sup>1</sup>, Gonzalo Molina<sup>1</sup>, Eduardo Fernández<sup>3</sup>



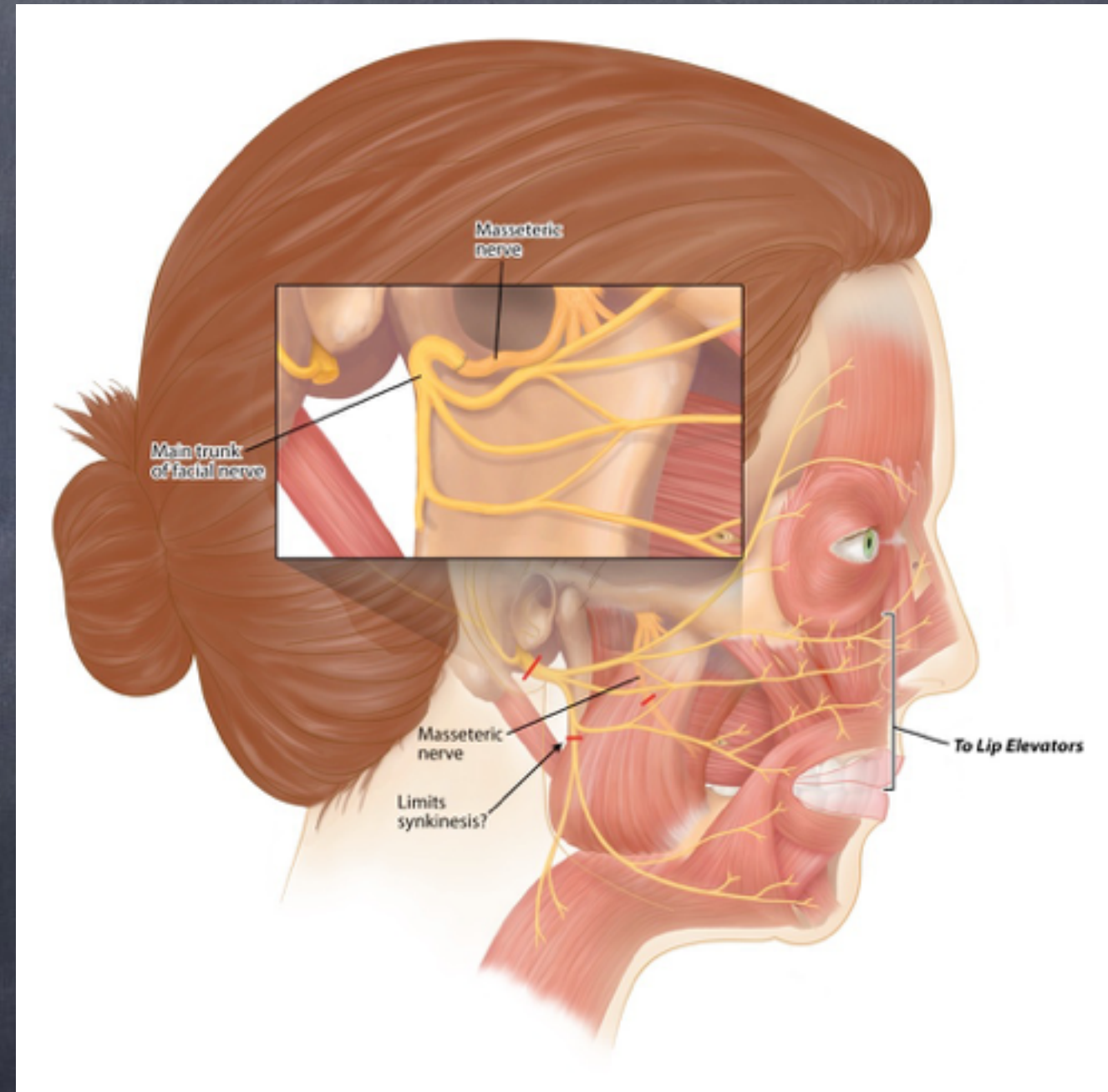
# Hypoglossal-Facial Nerve Transfer





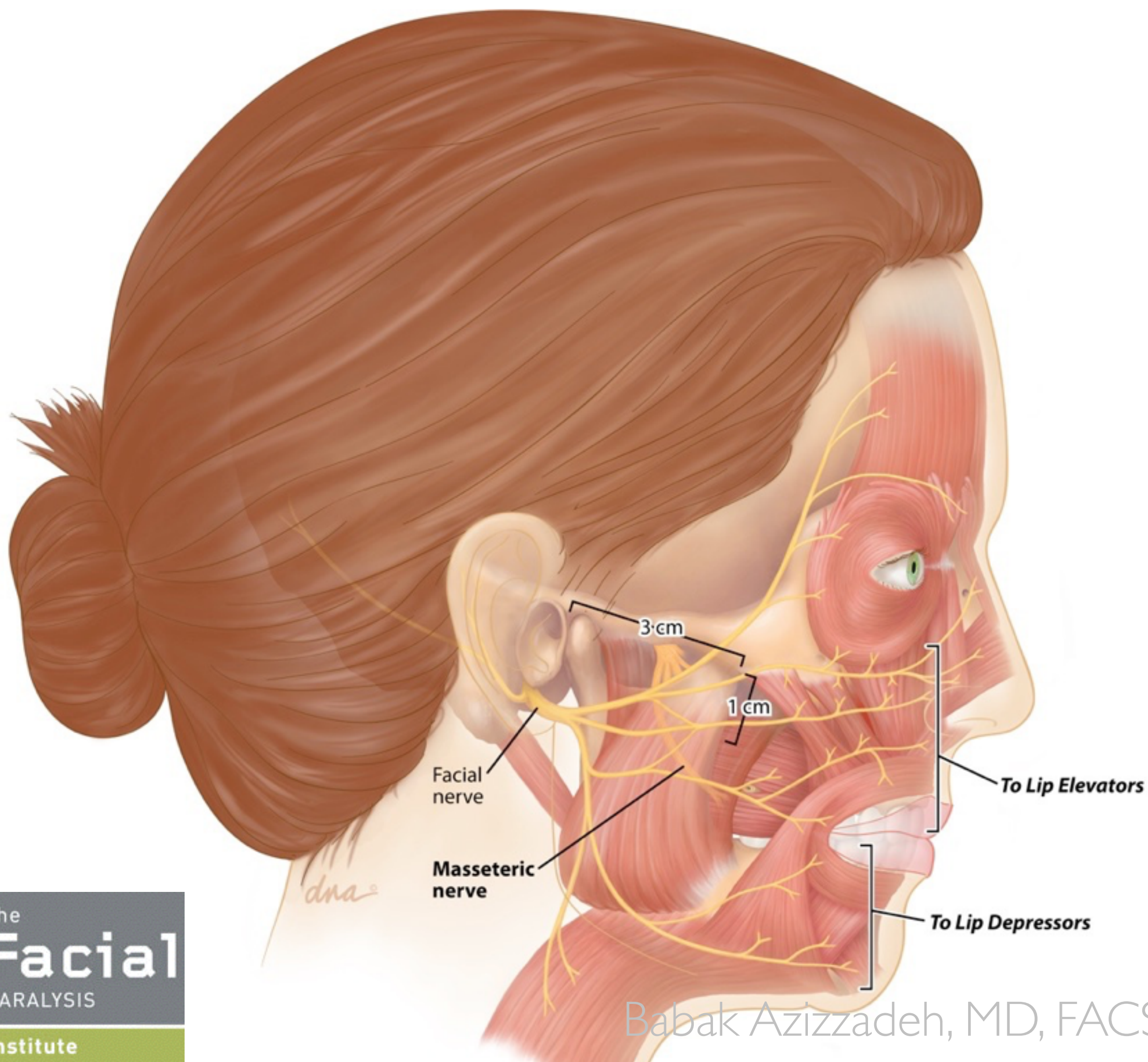
# Masseteric-Facial Nerve Transfer (5-7 Transfer)

- Utilizes the masseteric nerve (trigeminal nerve) to give nerve input into the facial nerve
- Creates resting facial tone & “moves” the face with clenching
- Results: Less synkinesis; better and earlier smile mechanism
- Can be used in patients with multiple nerve disorders, NF2, partial paralysis

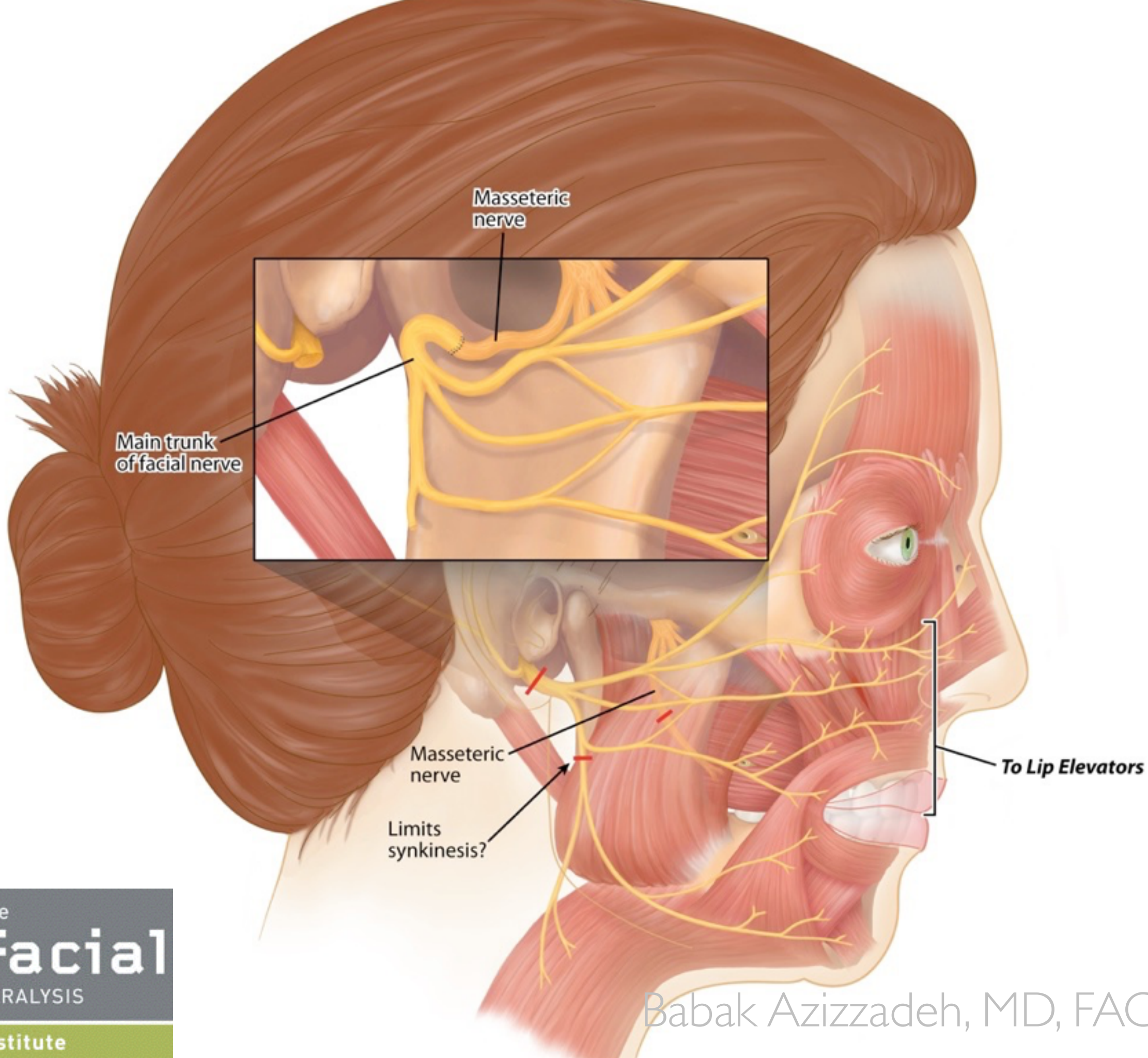


Babak Azizzadeh, MD, FACS













Pre-op



Post-op 4 mo









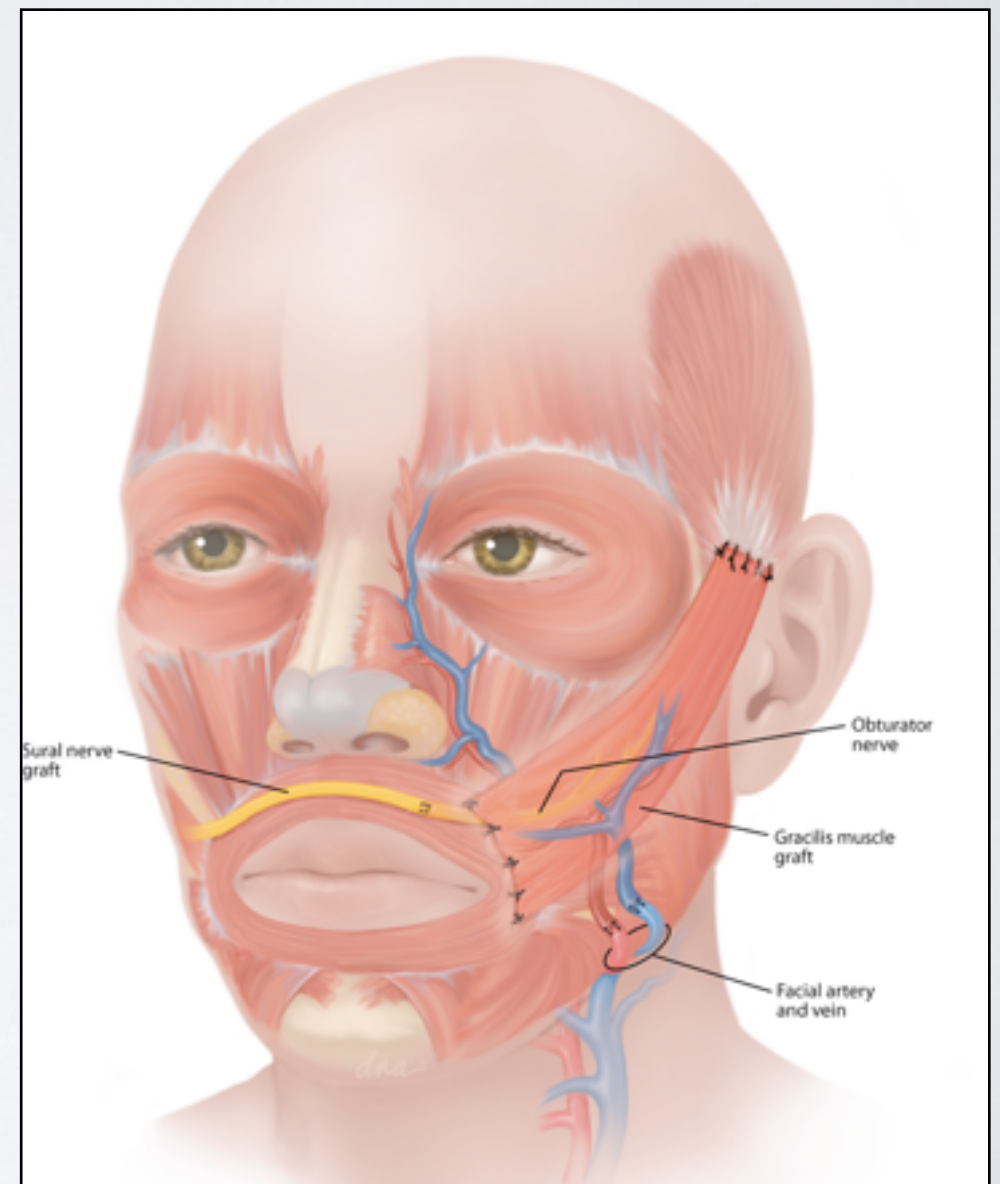
# masseteric-facial nerve transfer





# GRACILIS MUSCLE TRANSFER MOBILIZED BY THE NORMAL FACIAL NERVE ON THE NON-PARALYZED SIDE (CROSS FACIAL NERVE GRAFT)

- Utilizes normal facial nerve on the opposite side of the paralysis as the nerve source.
- New muscle is transferred to substitute for and/or complement the existing smile movement.
- Potential for dynamic smile with **spontaneous** and targeted facial movement.
- Helps both with smiling and during routine speech and communication.

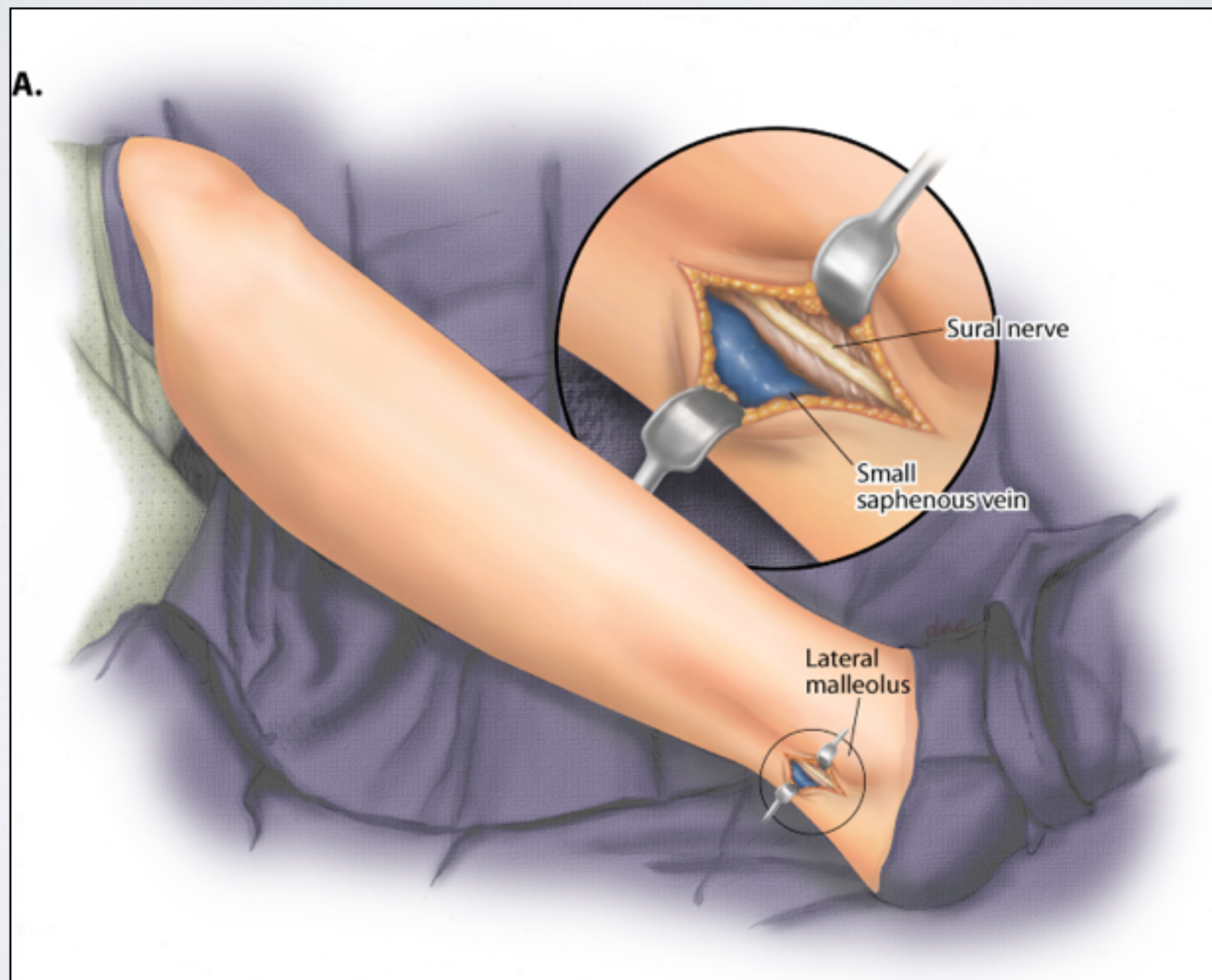


Babak Azizzadeh, MD, FACS



# STAGE 1

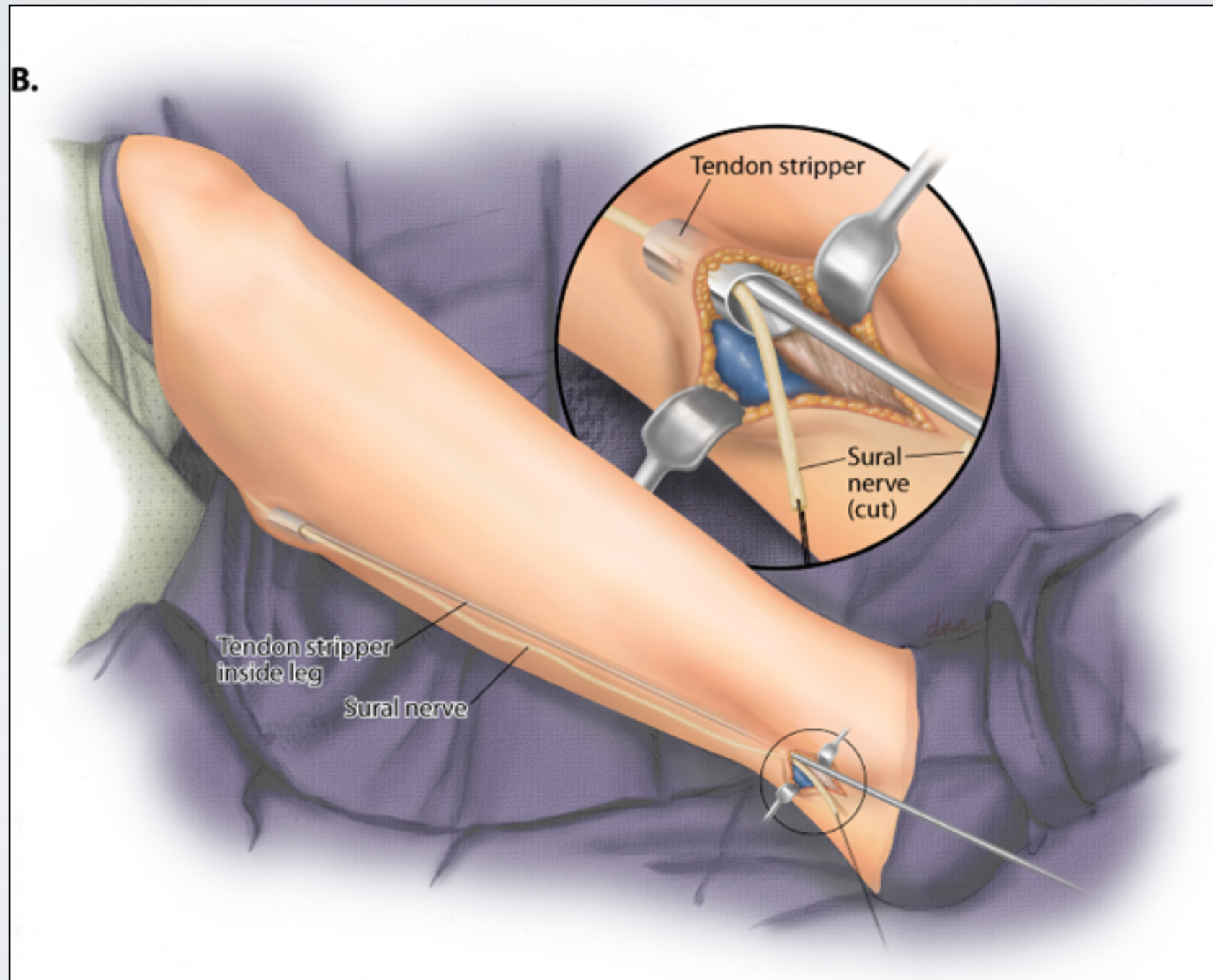
## SURAL NERVE HARVEST





# STAGE 1

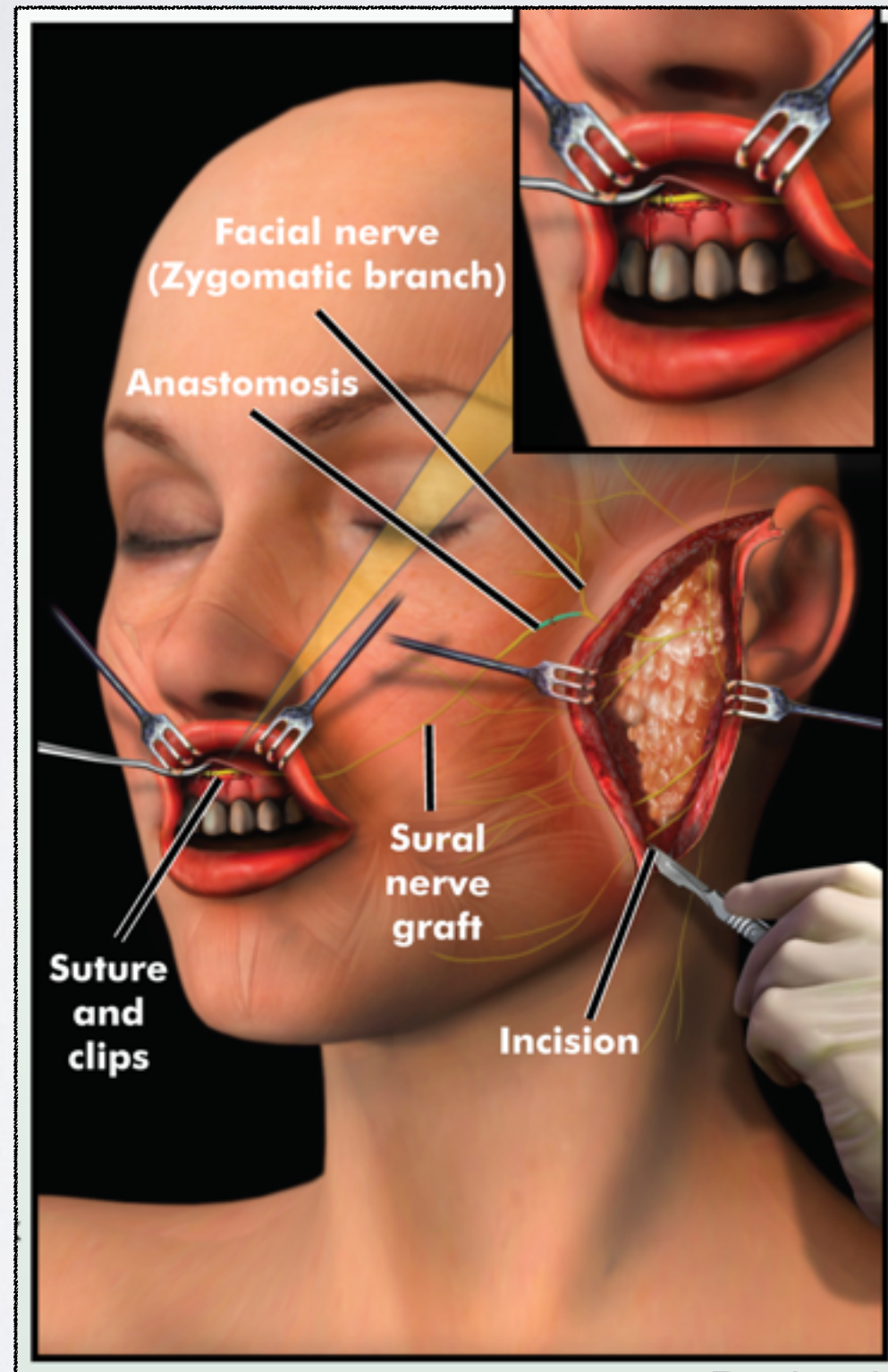
## SURAL NERVE HARVEST





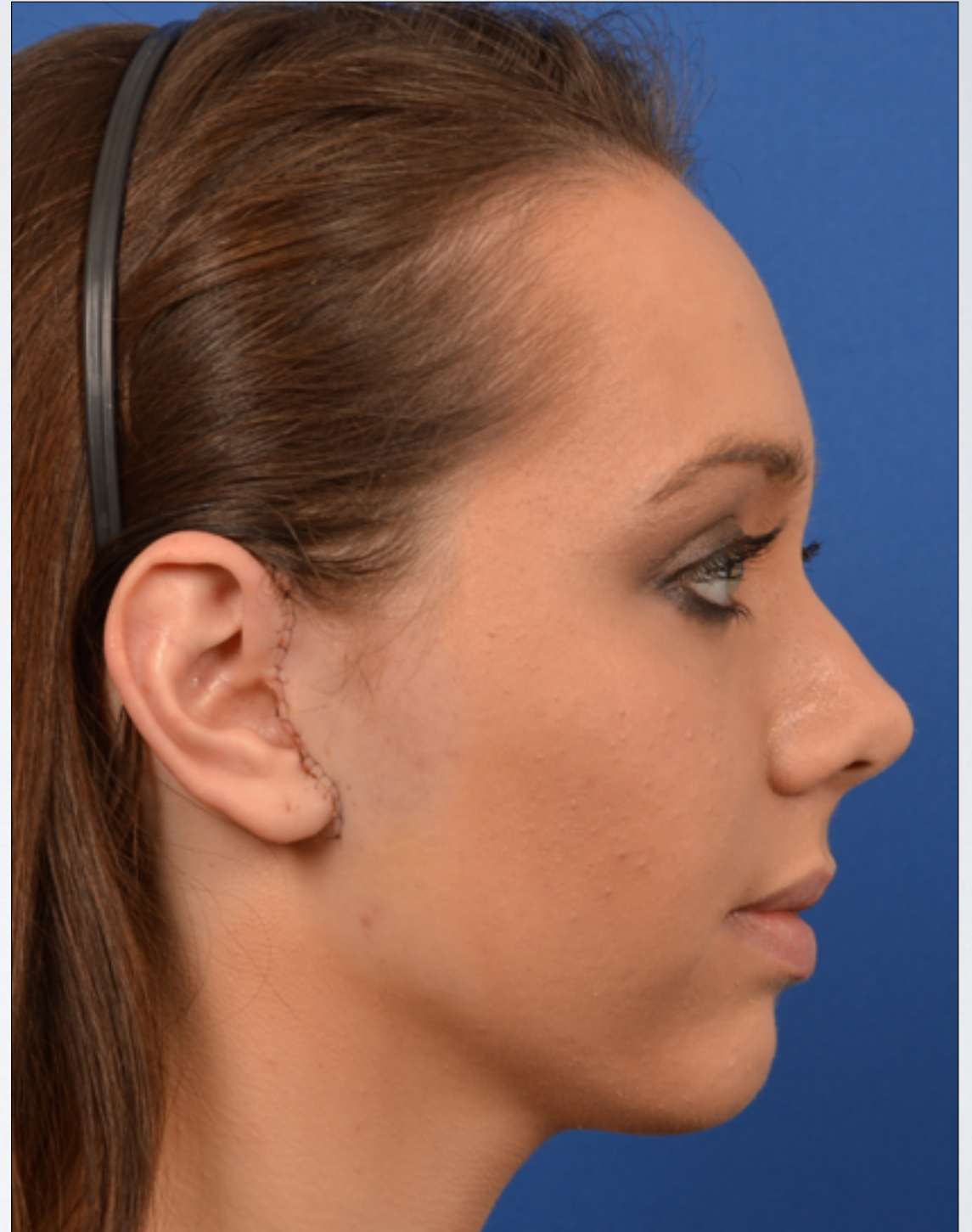
# STAGE 1

## CROSS FACIAL NERVE GRAFT





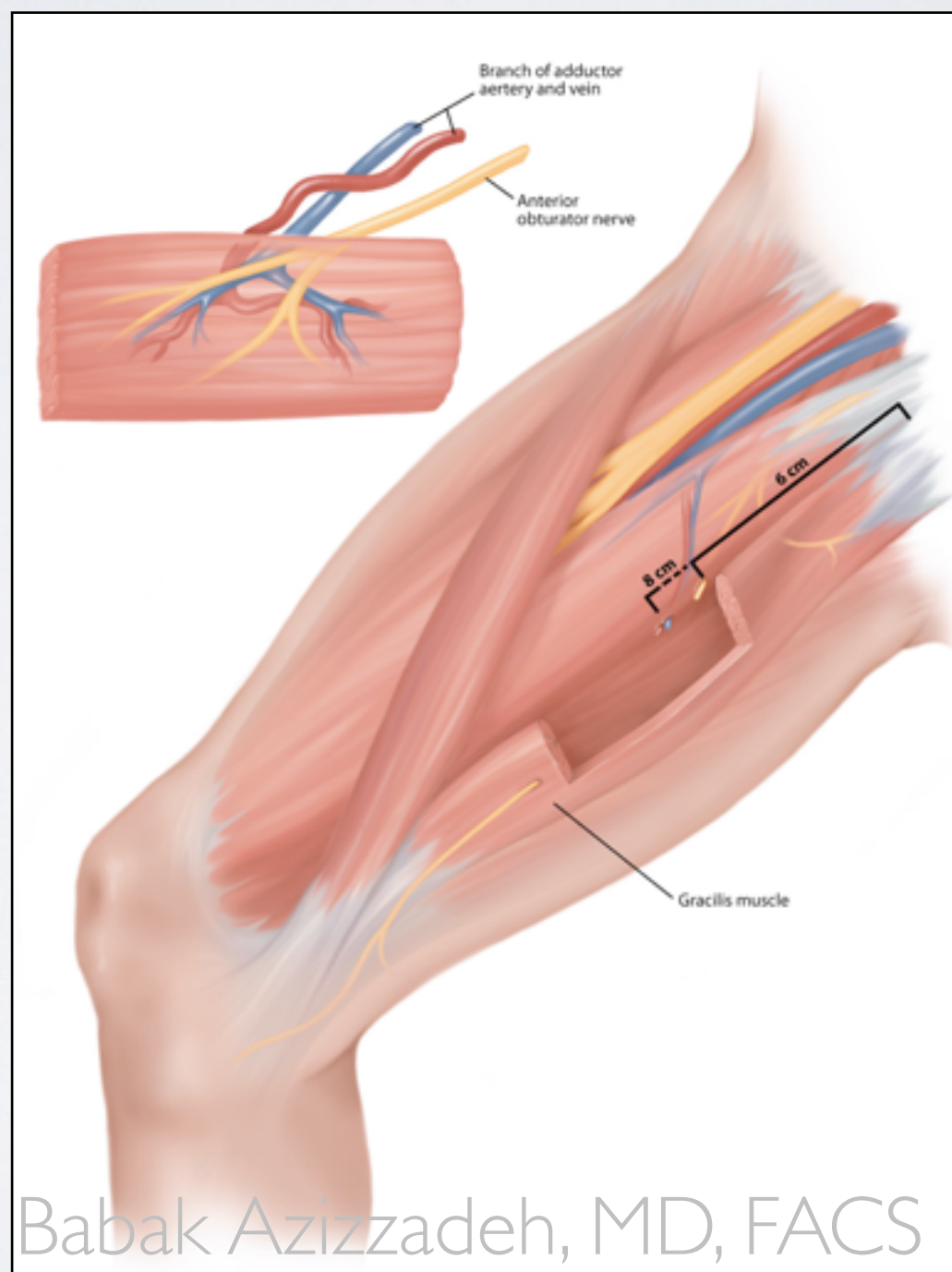
# INCISION AND RECOVERY AFTER 5 DAYS





# STAGE 2

## GRACILIS MUSCLE TRANSFER

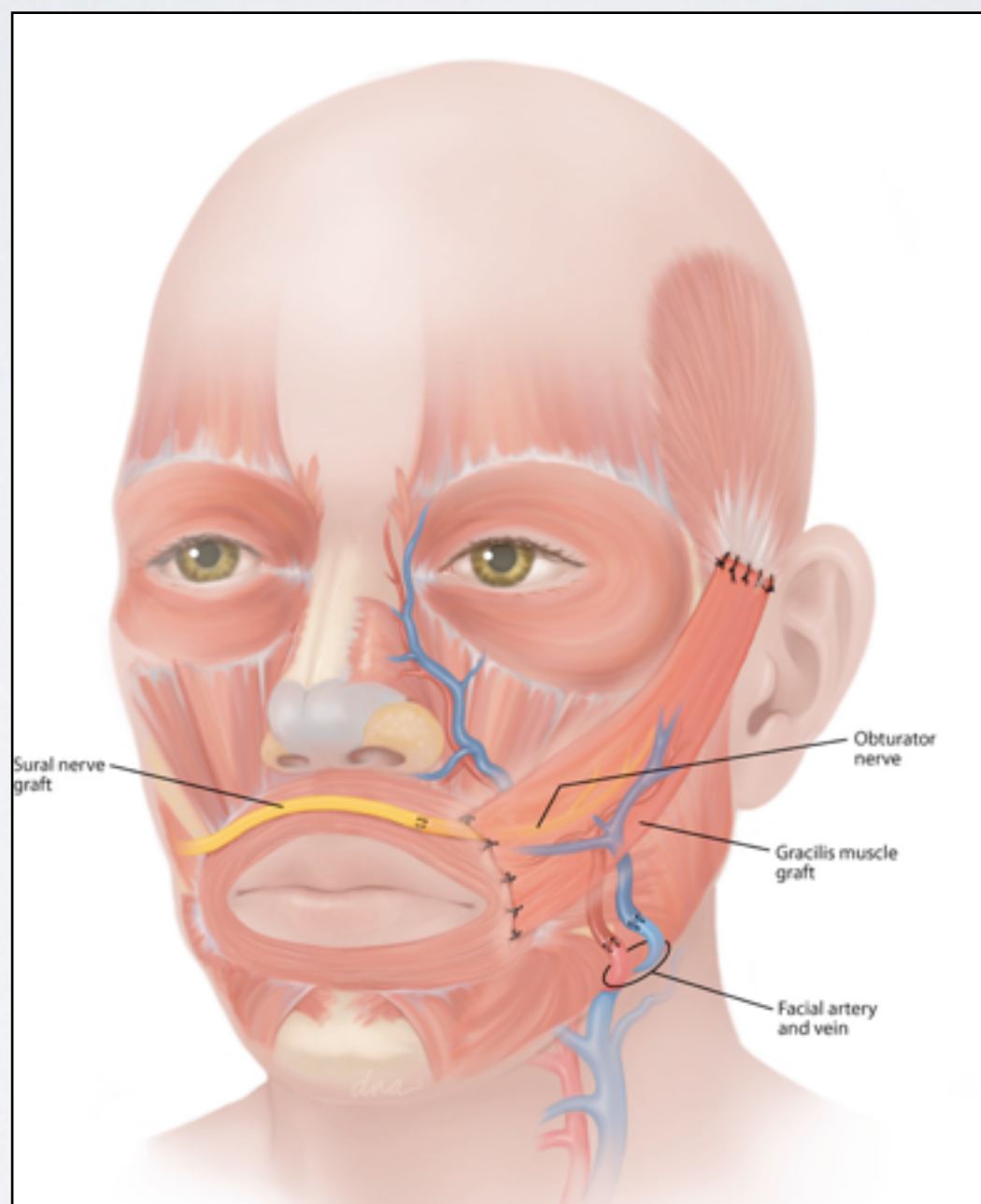


Babak Azizzadeh, MD, FACS



# STAGE 2

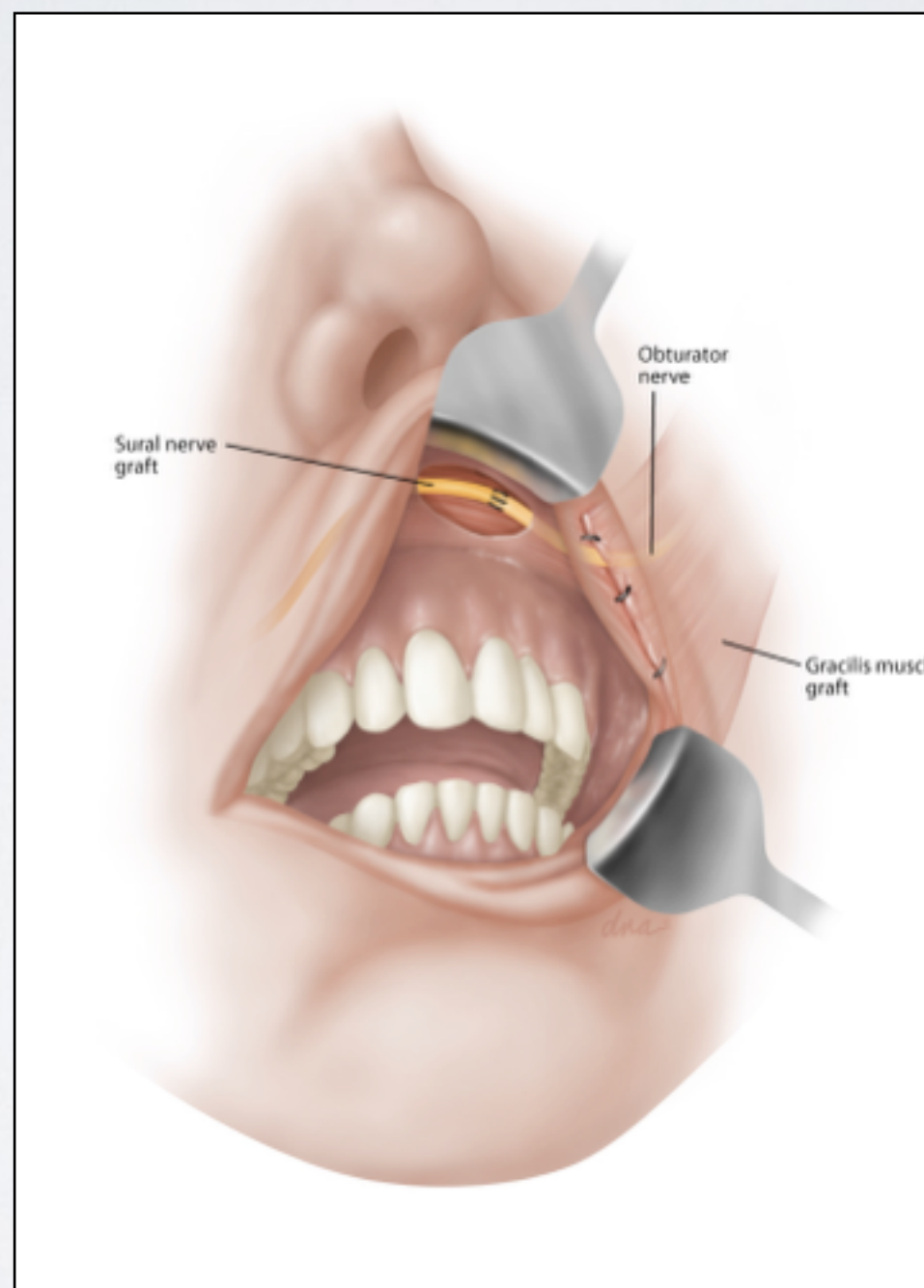
## GRACILIS MUSCLE TRANSFER





# STAGE 2

## GRACILIS MUSCLE TRANSFER



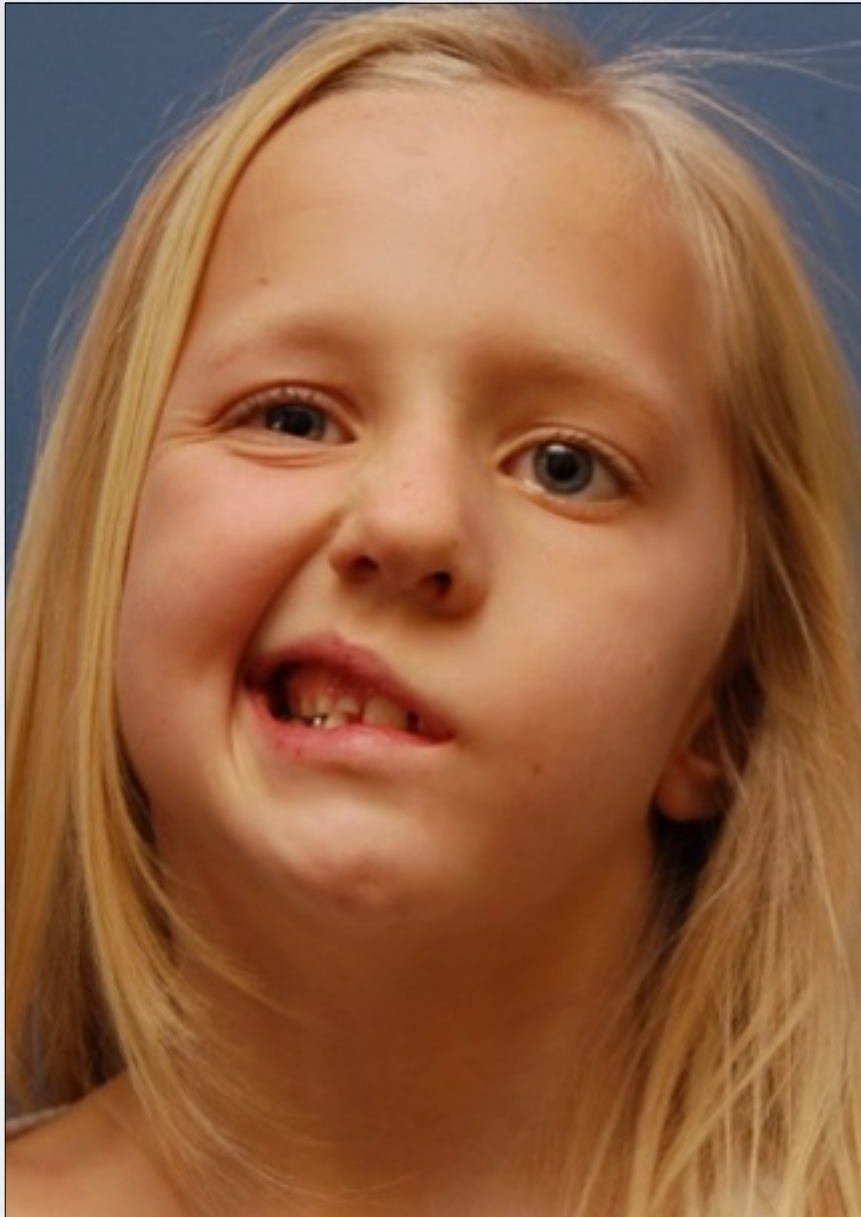

# Post-operative

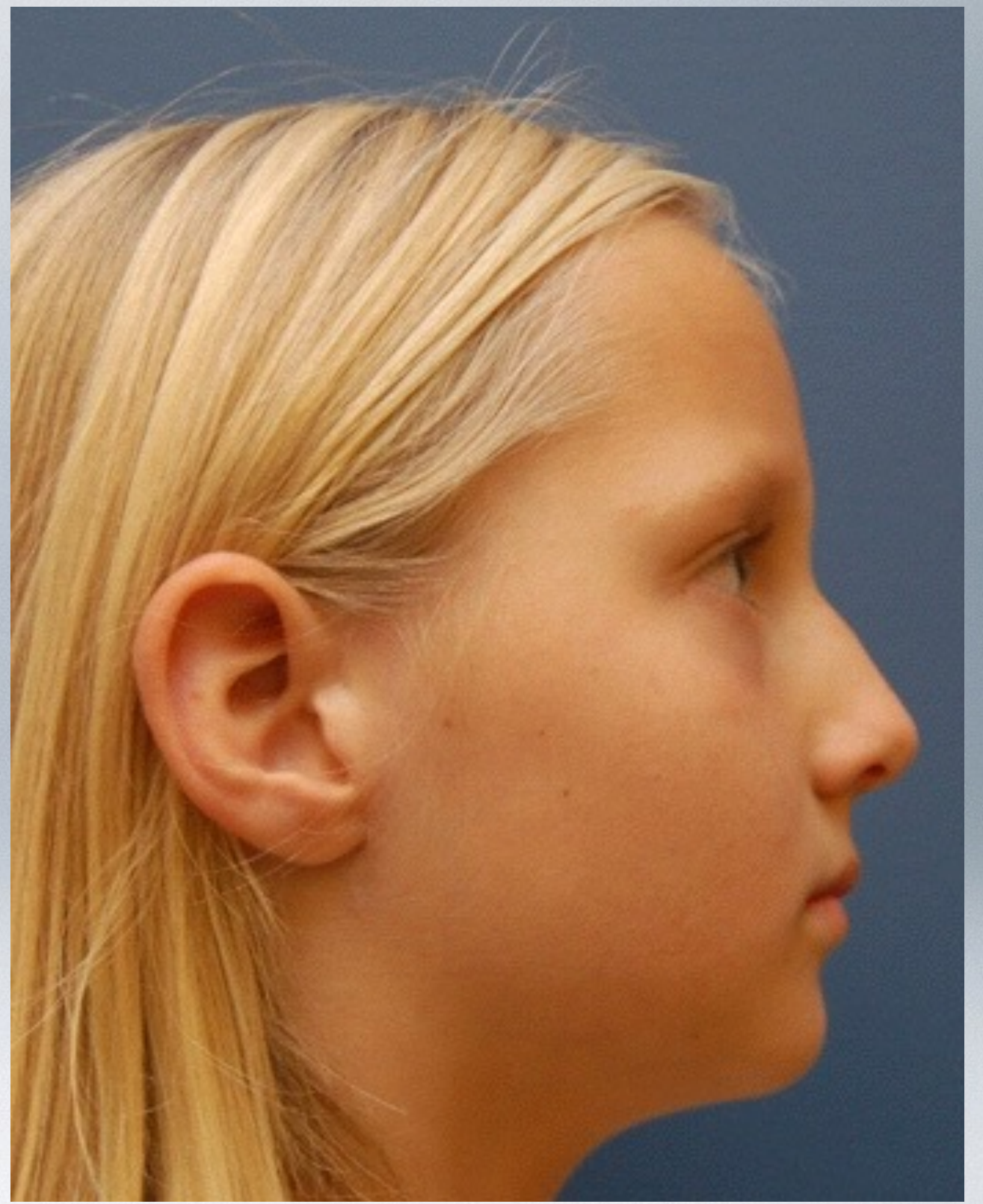
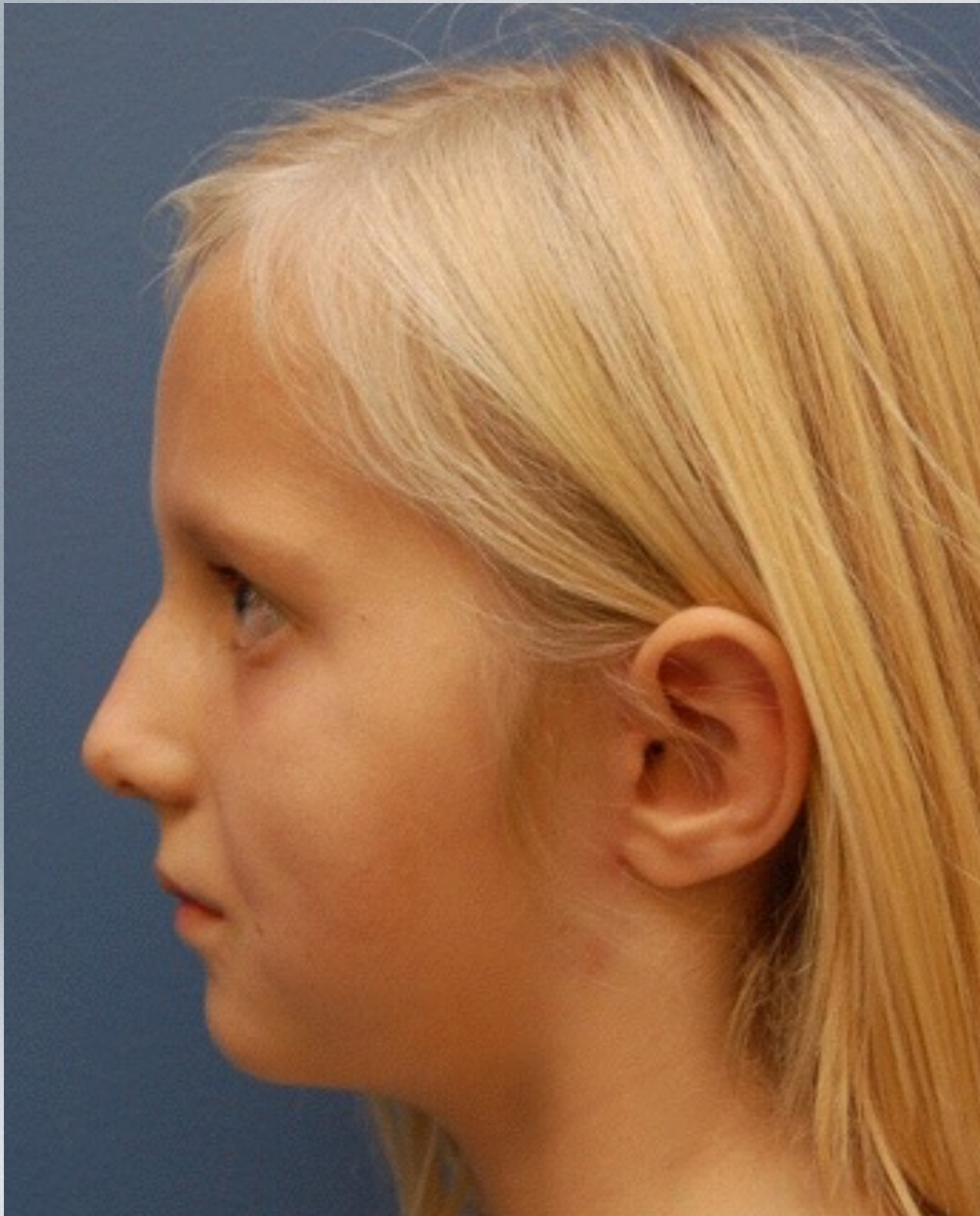- 10–15% of patients may require a touch up procedure to improve the symmetry of the gracilis flap and/or correct position of the laugh line and corner of the mouth
- Neuromuscular retraining
- Movement typically seen 6 mo after 2<sup>nd</sup> stage
- Muscle movement improves for up to 18 mo



# CROSS FACIAL NERVE GRAFT & GRACILIS MUSCLE TRANSFER

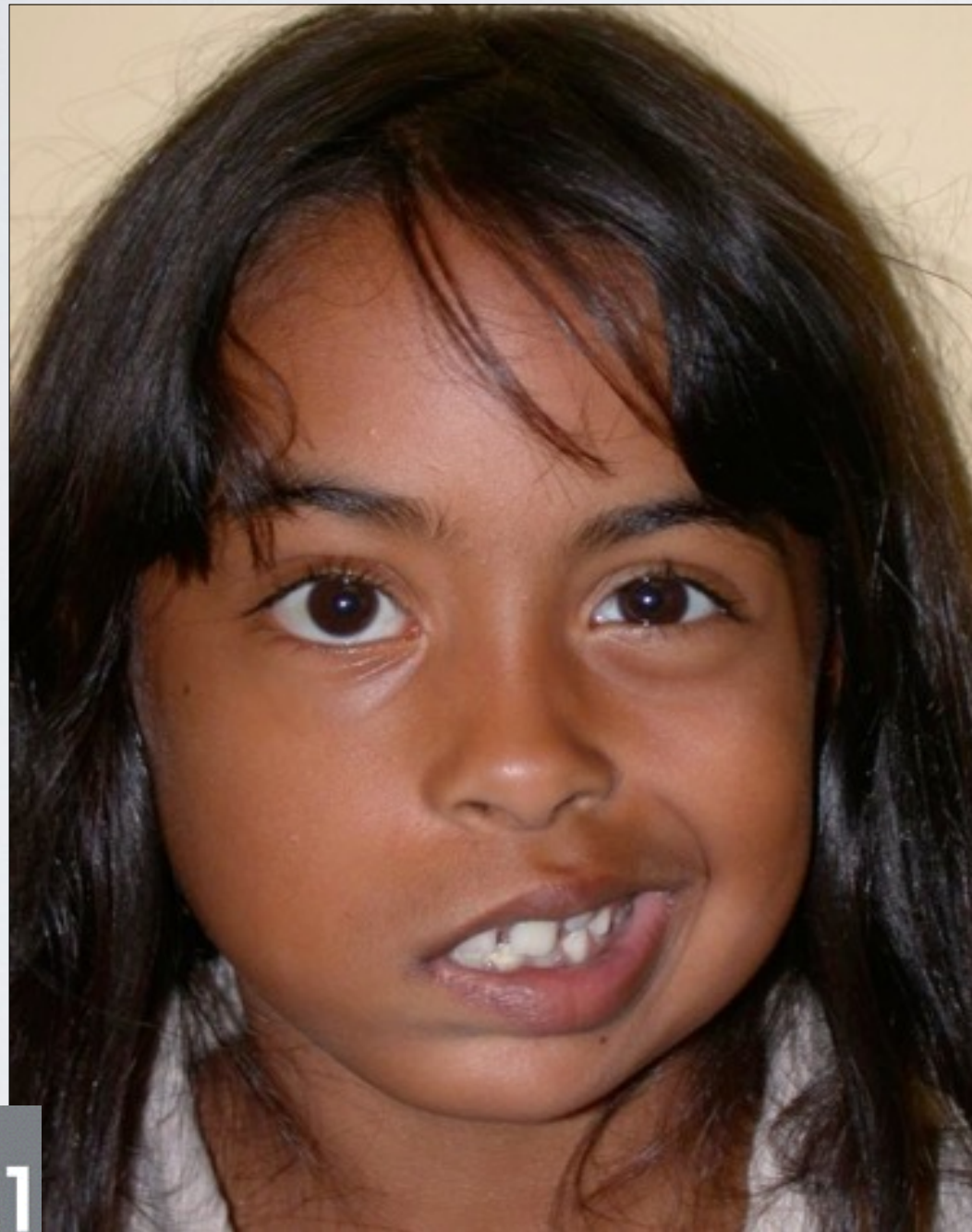






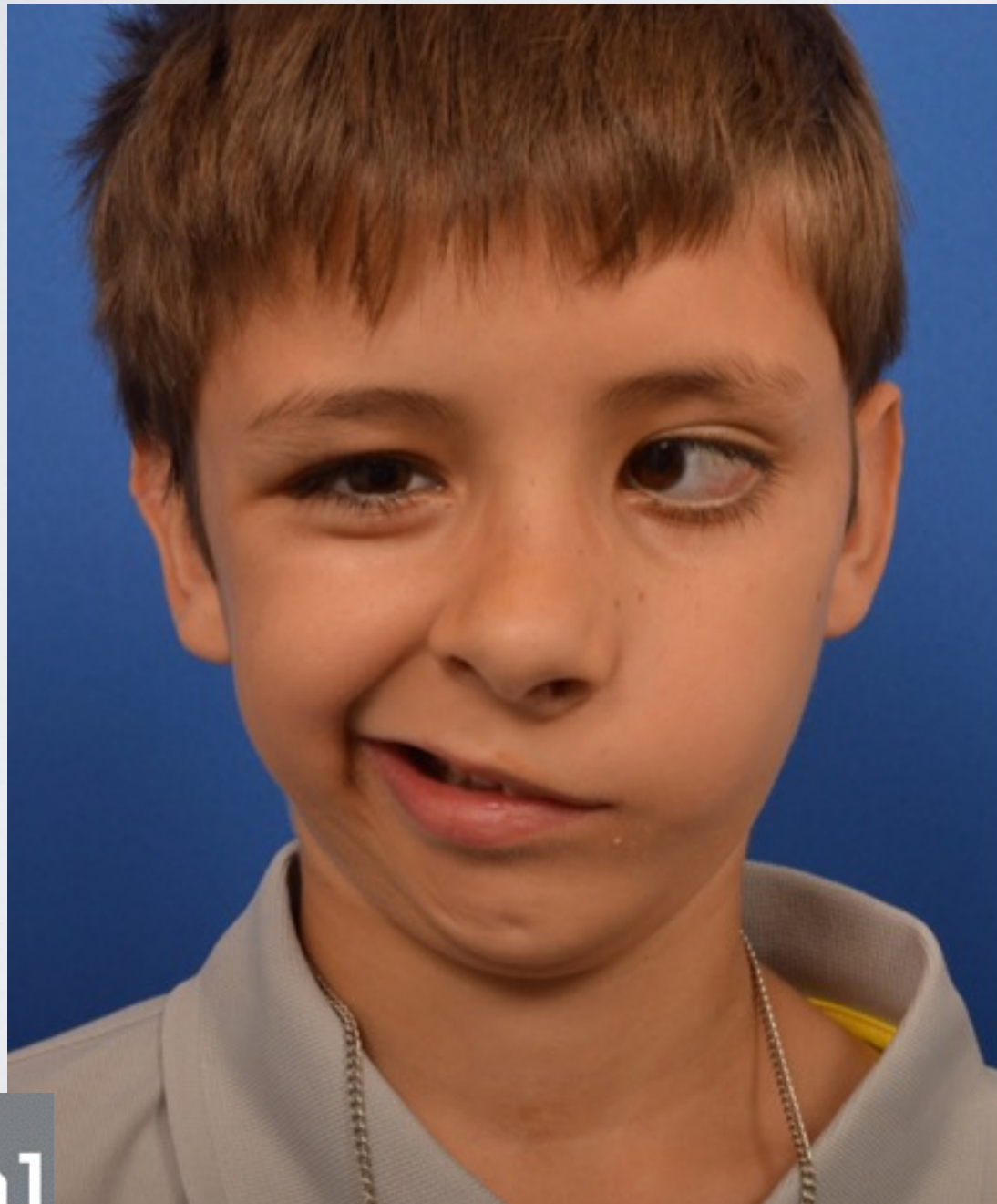

# CROSS FACIAL NERVE GRAFT & GRACILIS MUSCLE TRANSFER

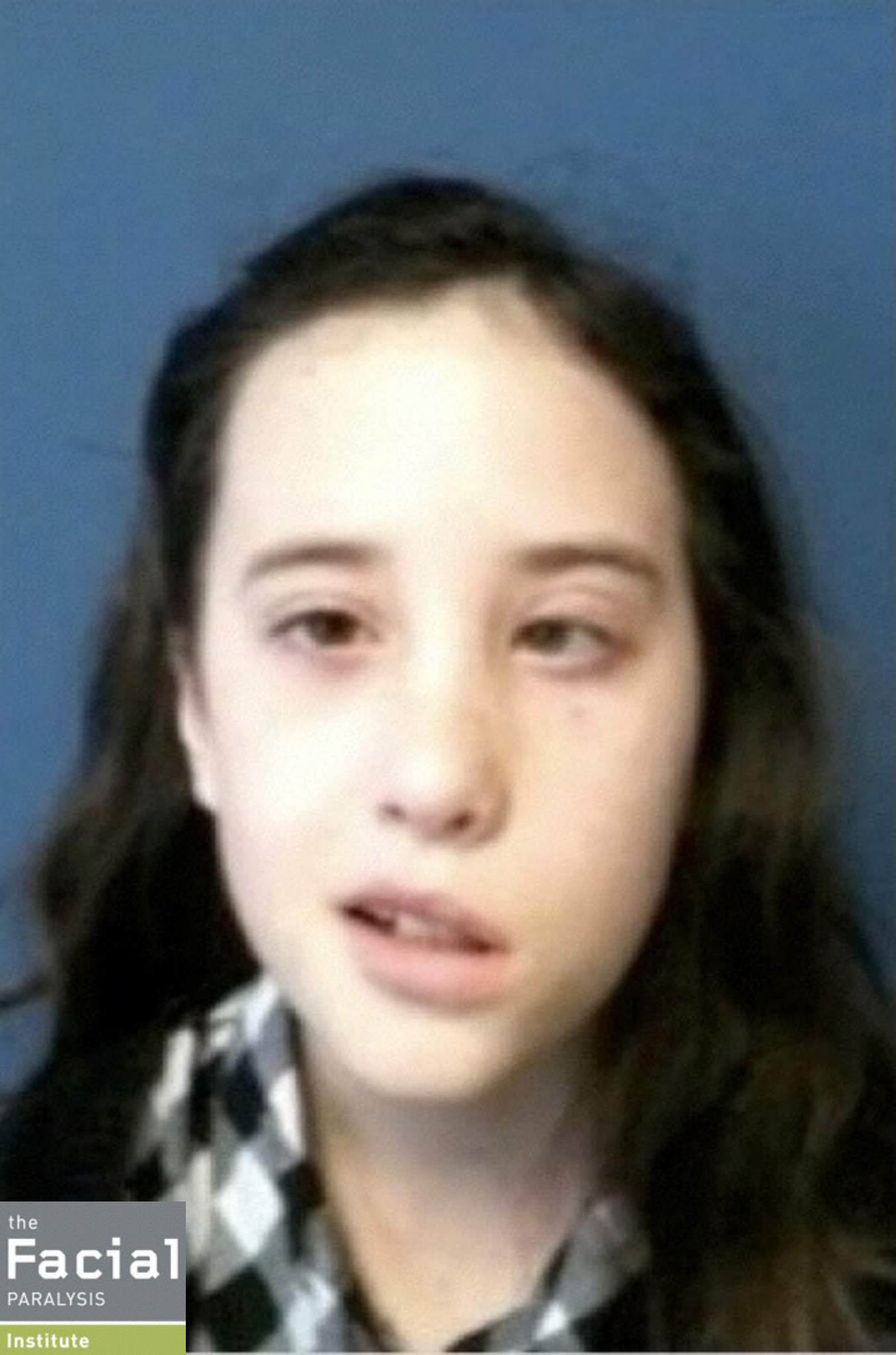




# CROSS FACIAL NERVE GRAFT & GRACILIS MUSCLE TRANSFER



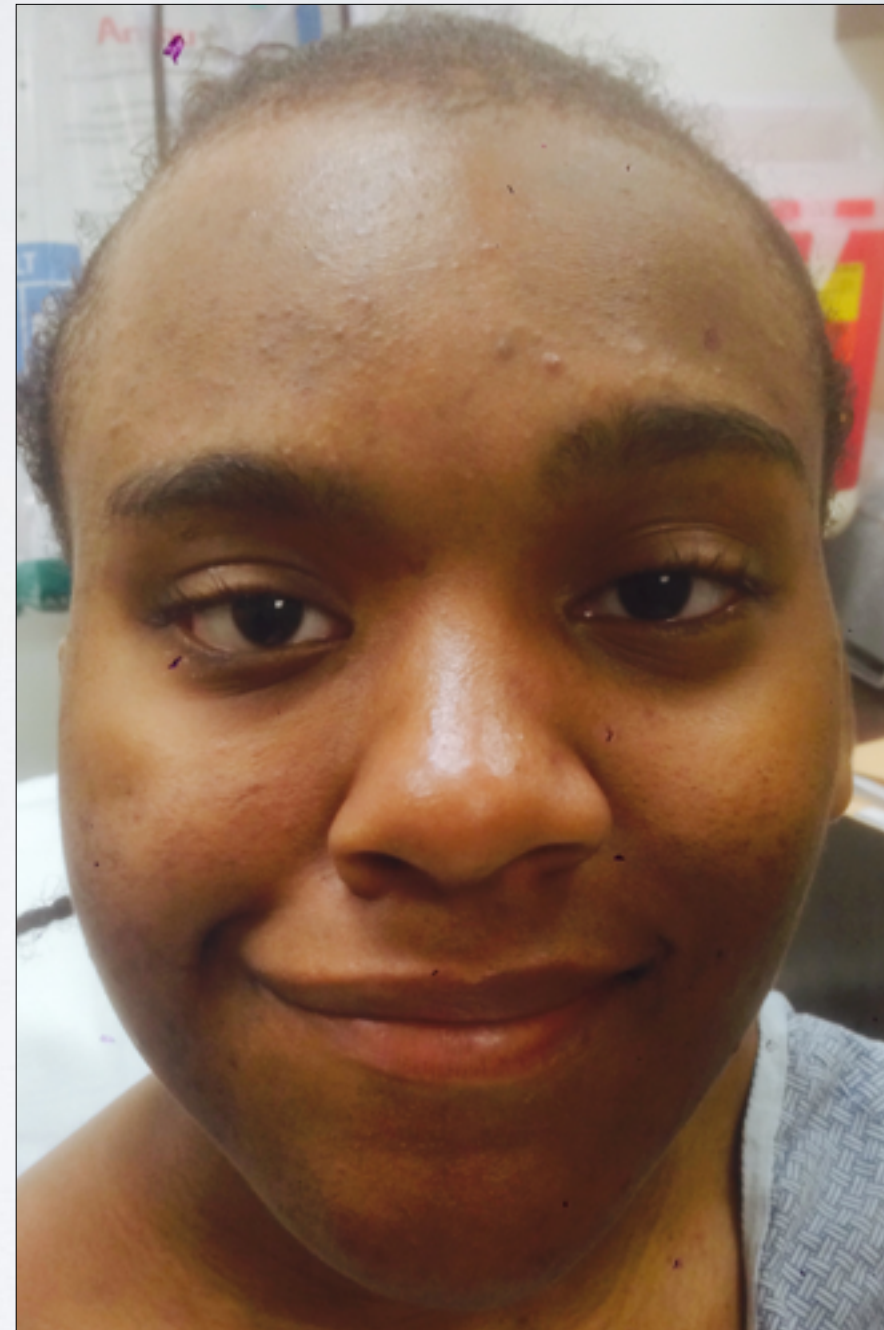






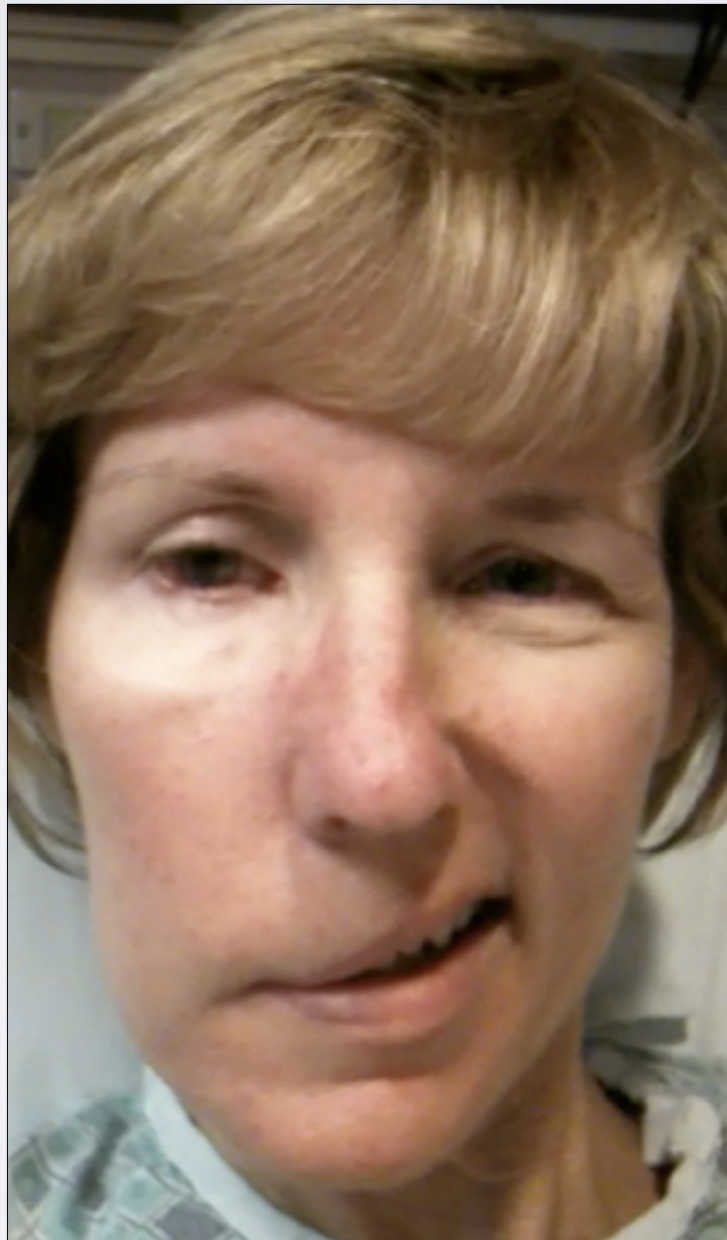
# 10 Year Follow-up

Cross Facial Nerve Graft & Gracilis Muscle Transfer





# CROSS FACIAL NERVE GRAFT & GRACILIS MUSCLE TRANSFER

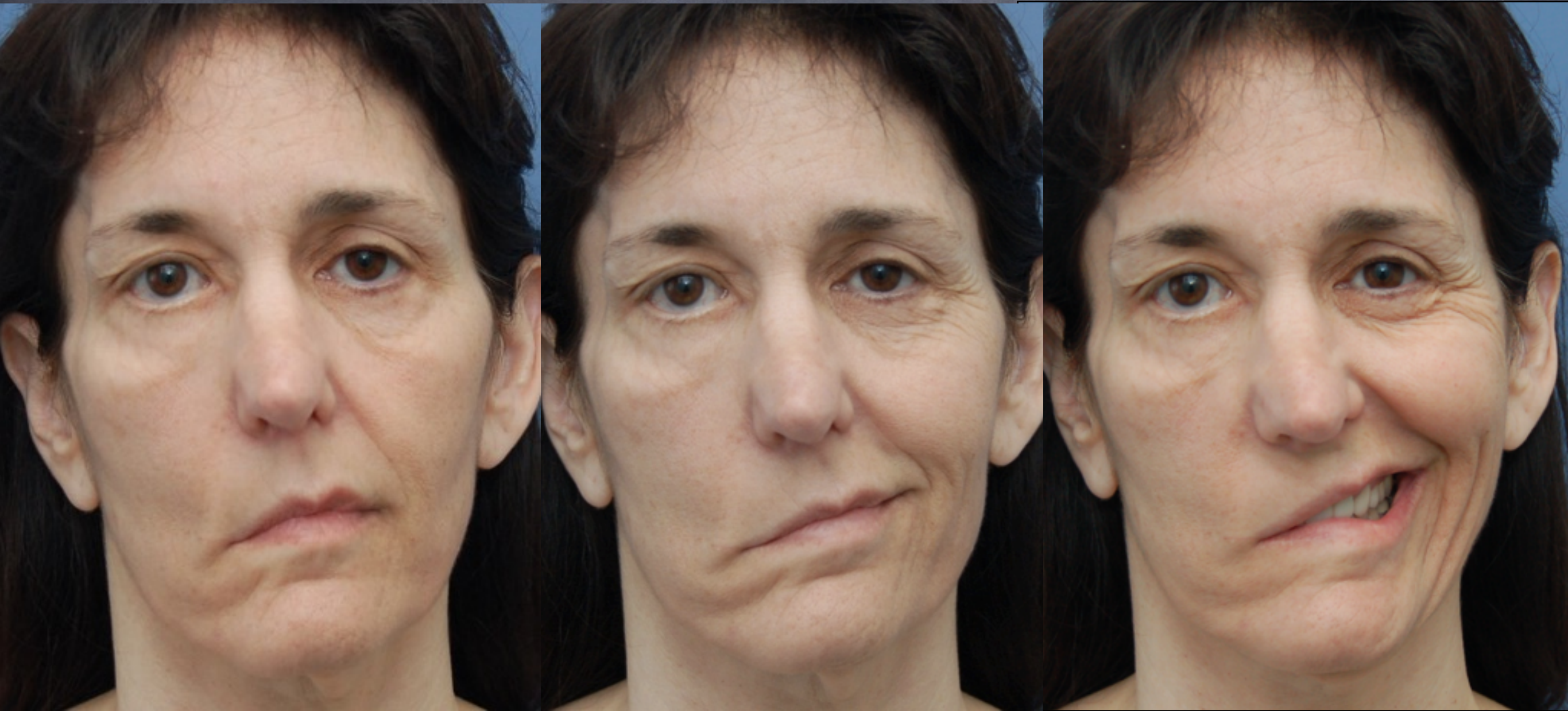



# COMBINATION TREATMENTS

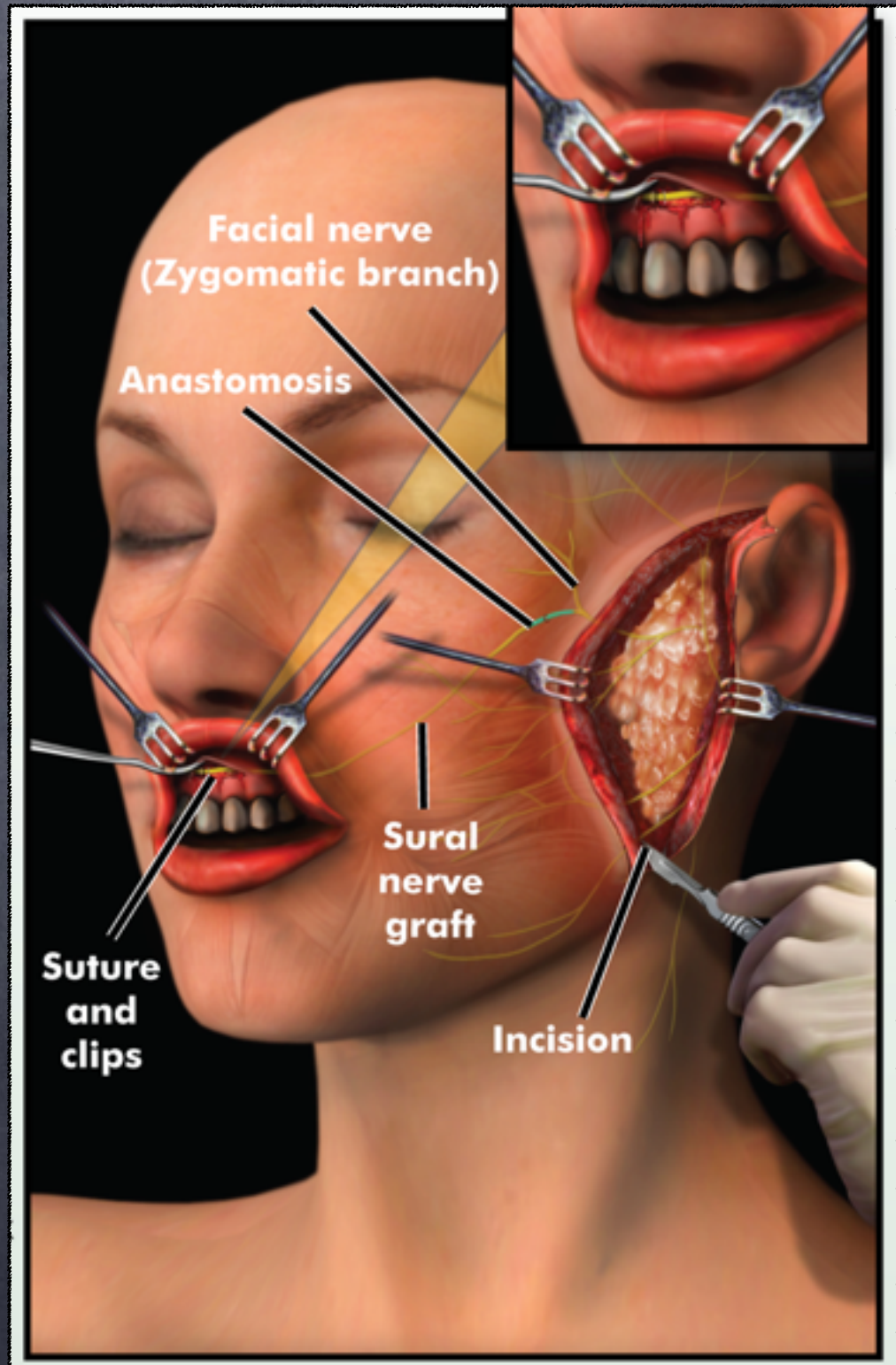
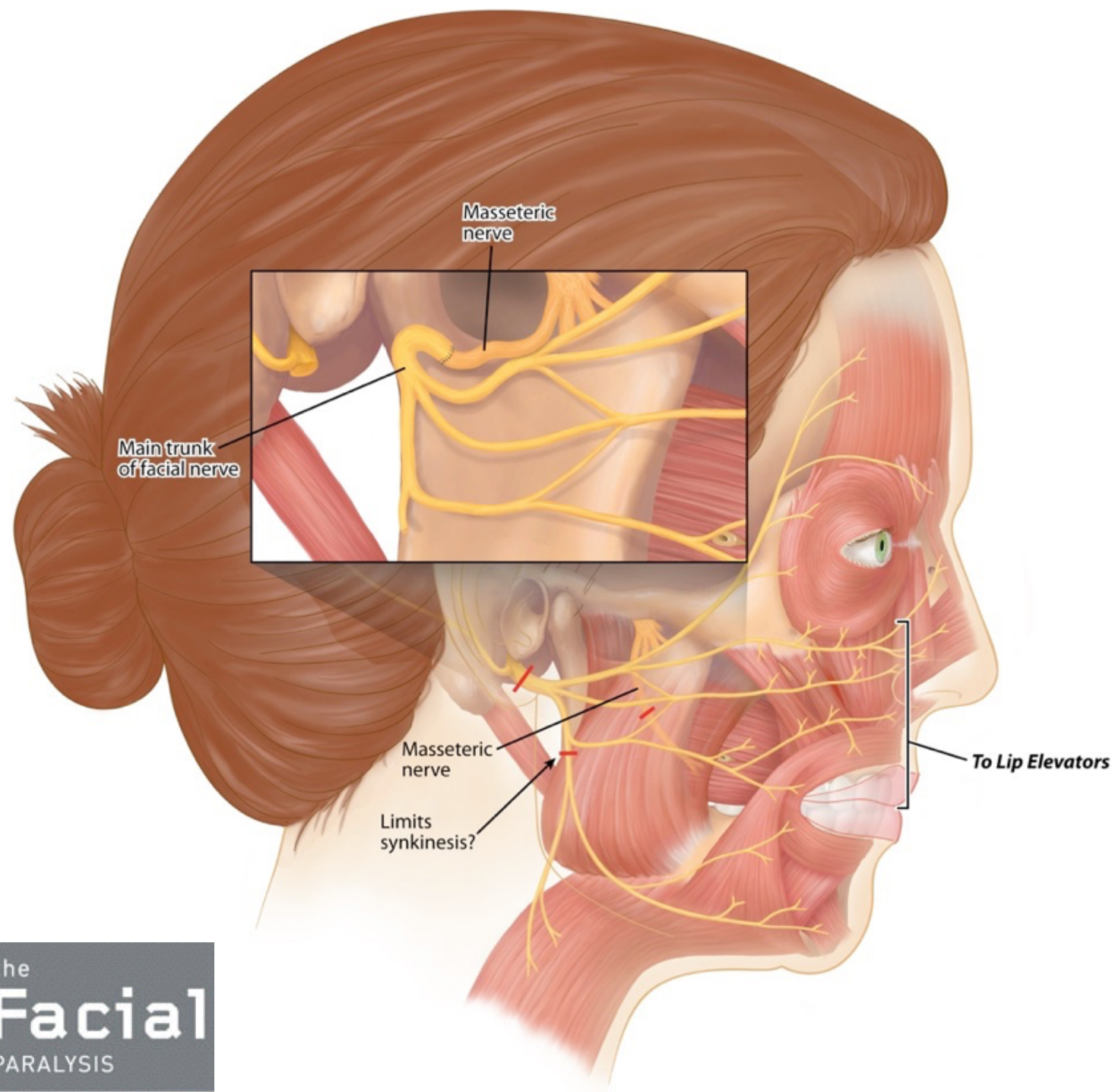


# Right Facial Paralysis 18 mo Duration Secondary to Acoustic Neuroma Surgery





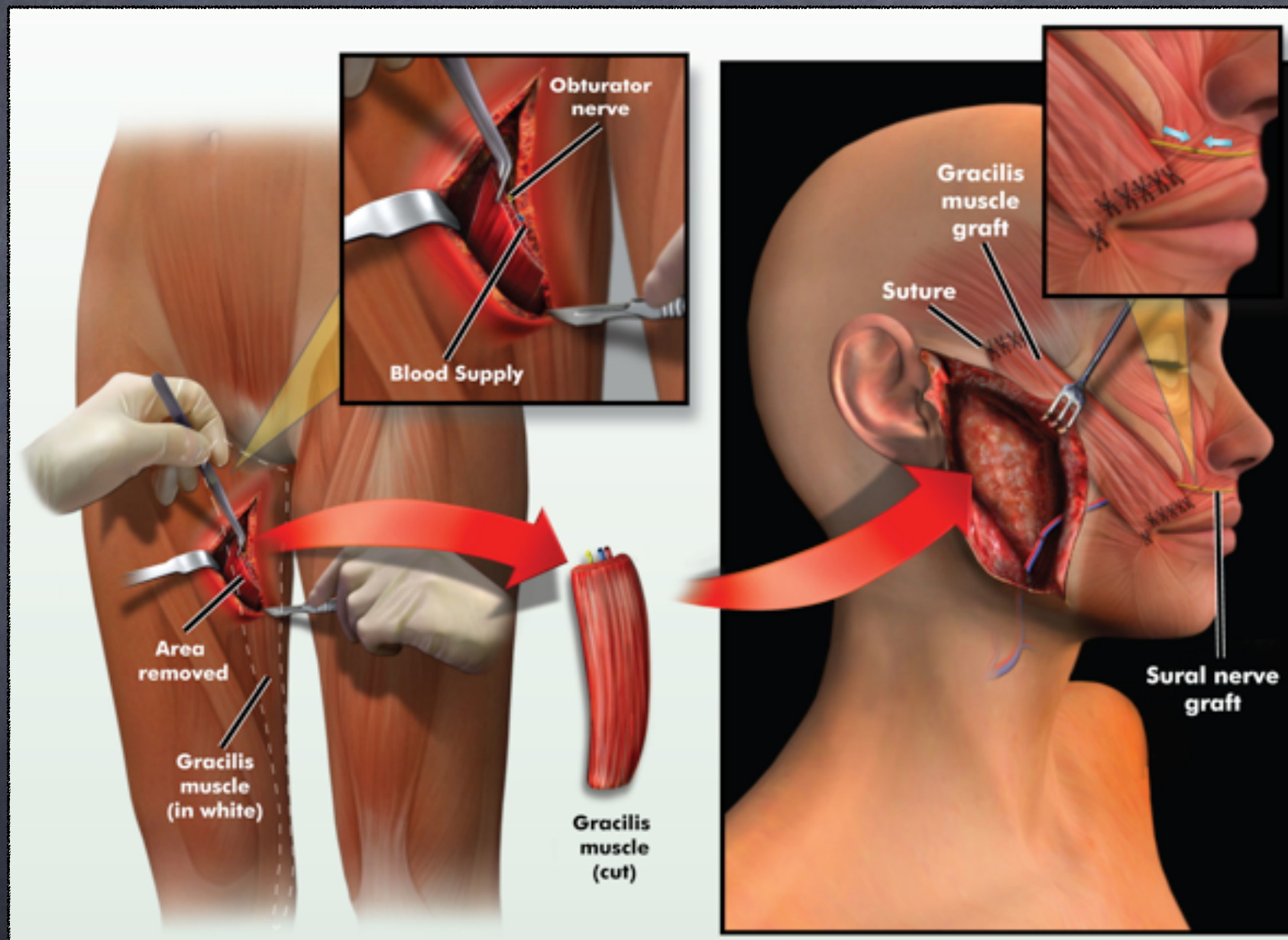
# Stage 1: Masseteric-Facial Nerve Transfer, Cross Facial Nerve Graft





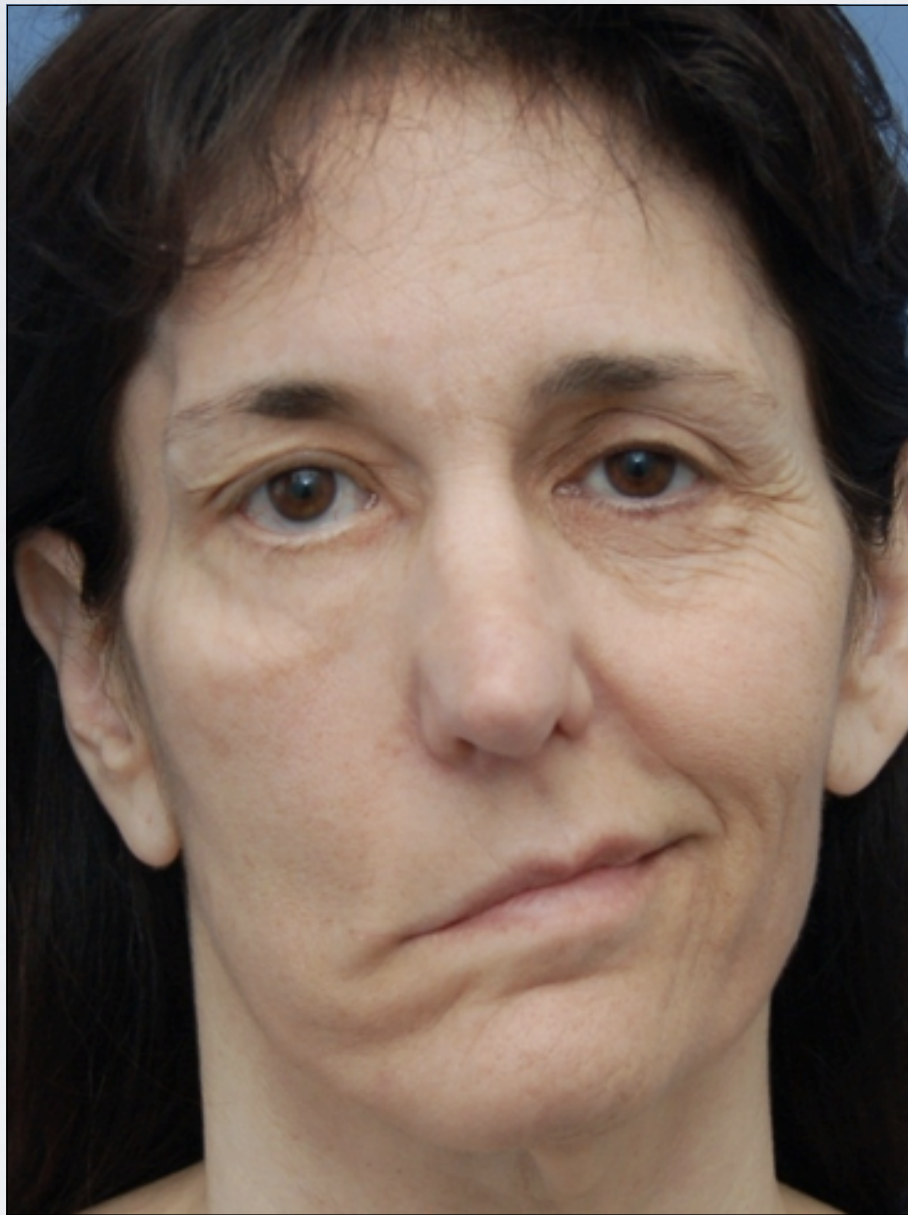## Stage 2

# Gracilis Muscle Transfer






# MASSETERIC-FACIAL NERVE GRAFT WITH CROSS FACIAL NERVE GRAFT & GRACILIS MUSCLE TRANSFER; FILLERS FOR TEMPLE ATROPHY AND BOTOX

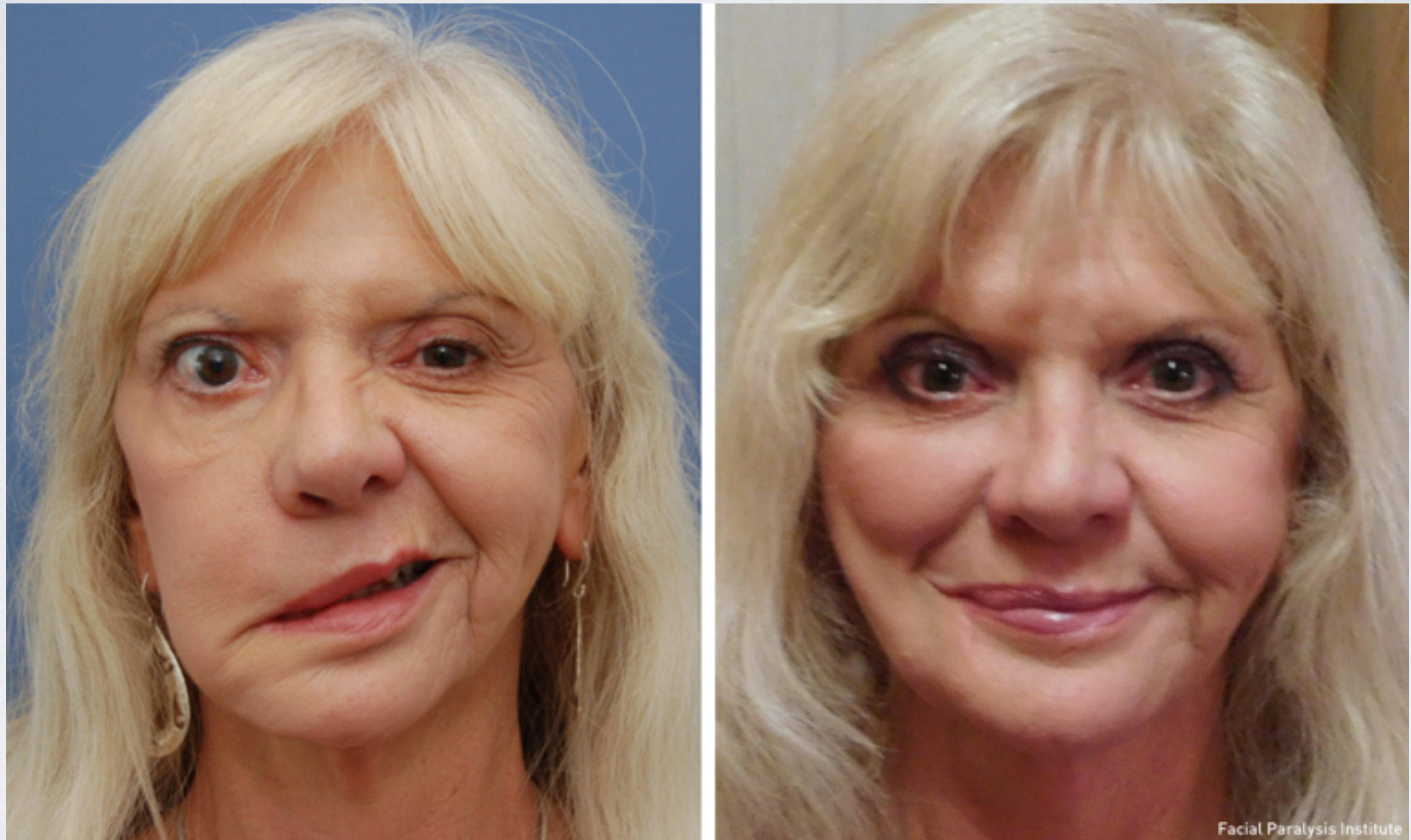







# MASSETERIC-FACIAL NERVE GRAFT WITH CROSS FACIAL NERVE GRAFT & GRACILIS MUSCLE TRANSFER





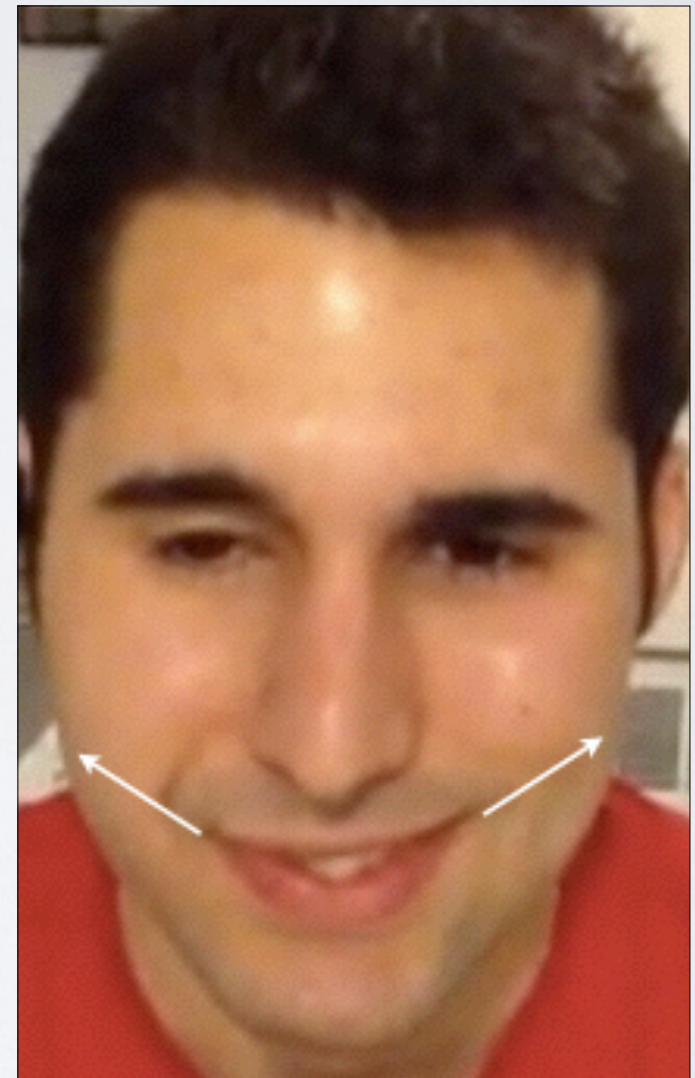
# Hypoglossal-Facial Nerve Transfer (12-7) Cross Facial Nerve Graft (CFNG) & Gracilis Muscle Transfer



Pre-op

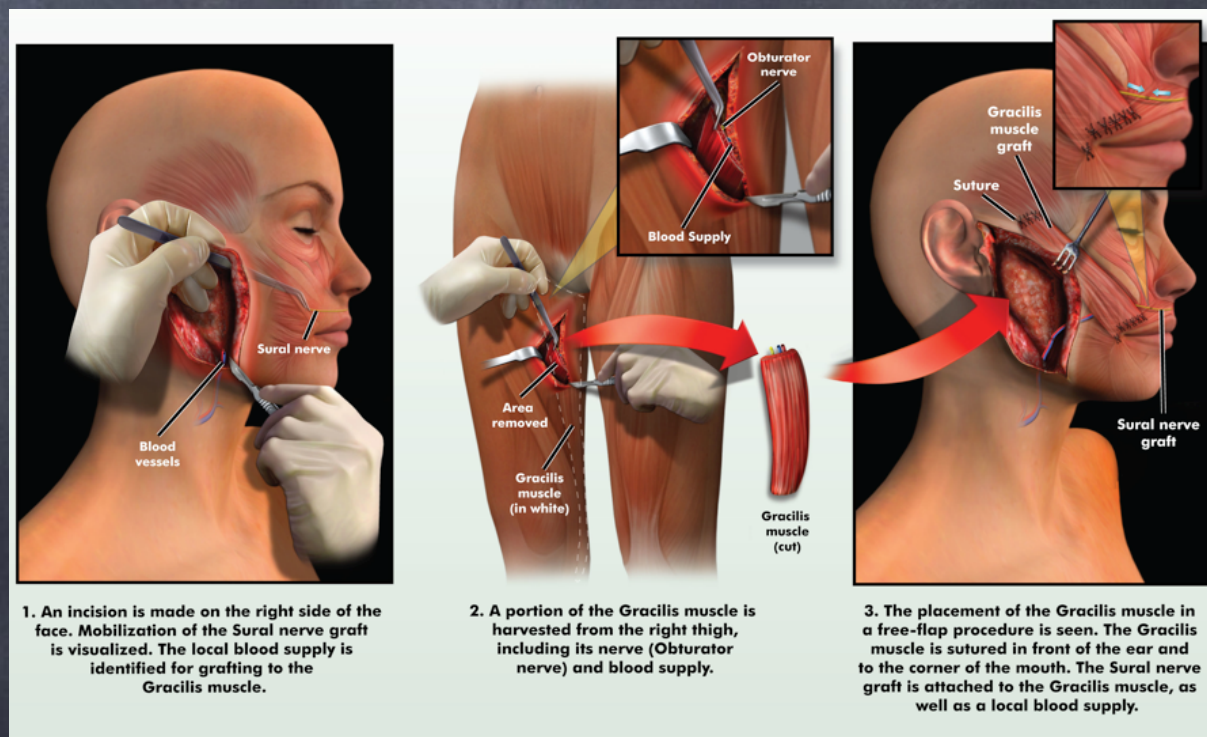
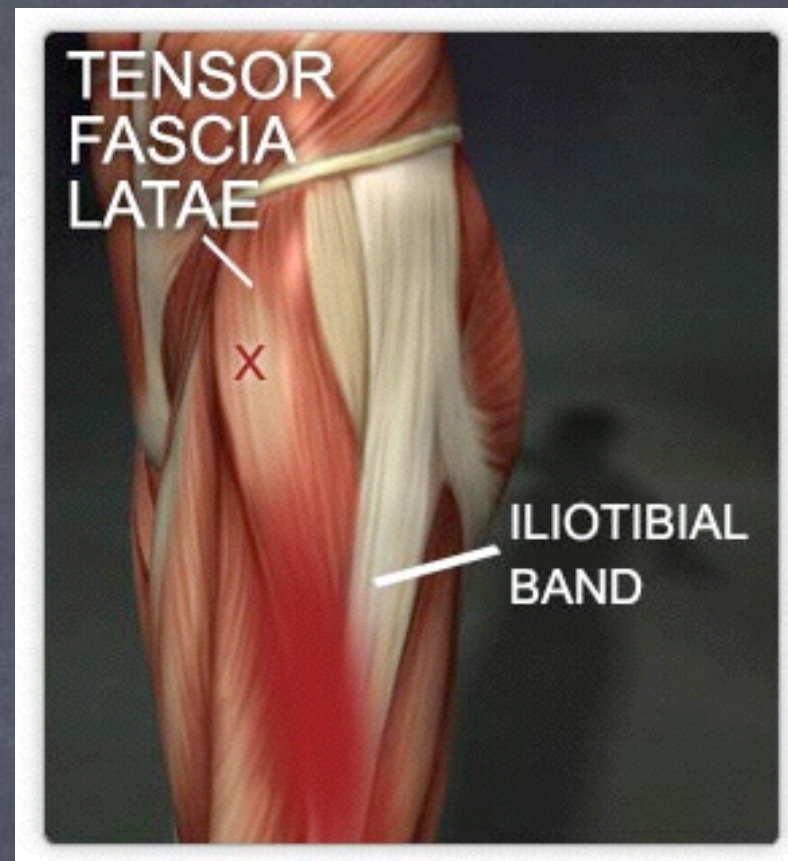


12-7



12-7 & CFNG-Gracilis





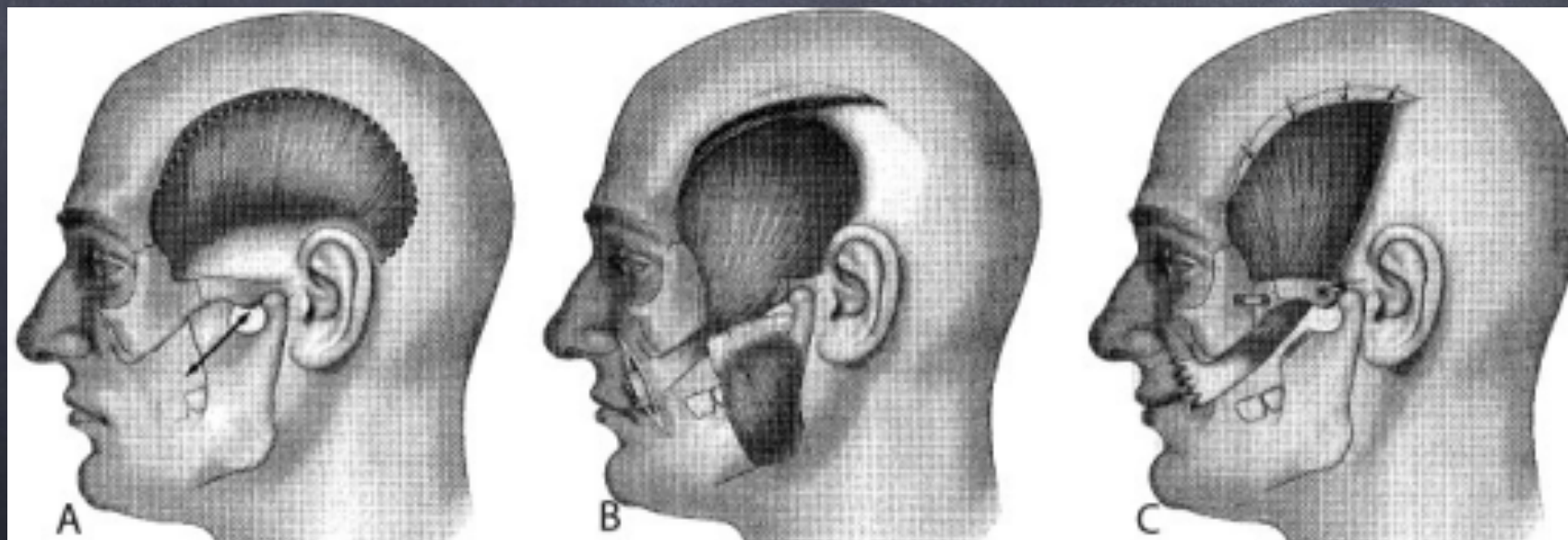






# Temporalis Transfer

- Temporalis Muscle: Chewing muscle; Trigeminal nerve (cranial nerve V)
- Muscle or muscle tendon is secured to corner of mouth to help lift and allow conscious smile
- Excellent static procedure and conscious dynamic movement
- Conscious smile initiated by biting down



A comprehensive approach to long-standing facial paralysis based on lengthening temporalis myoplasty. Labbè D, Bussu F, Iodice A - Acta Otorhinolaryngol Ital (2012)



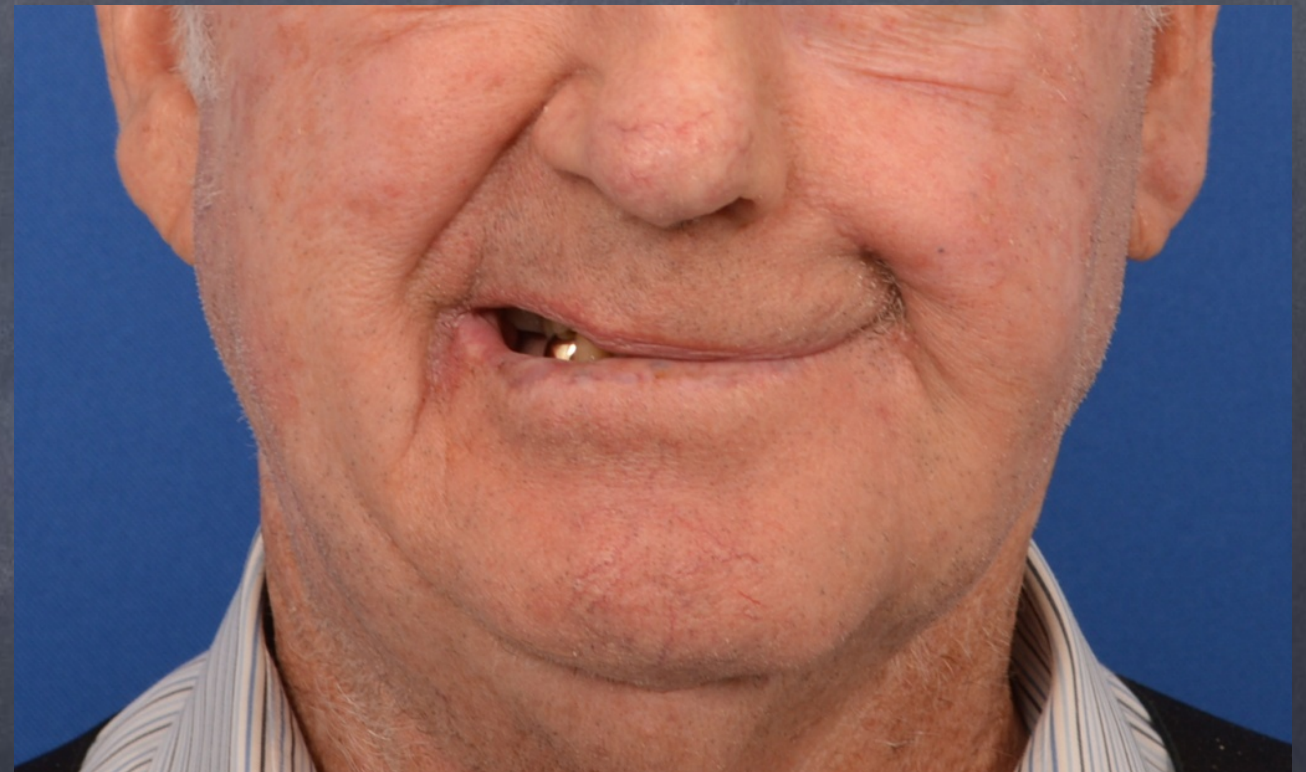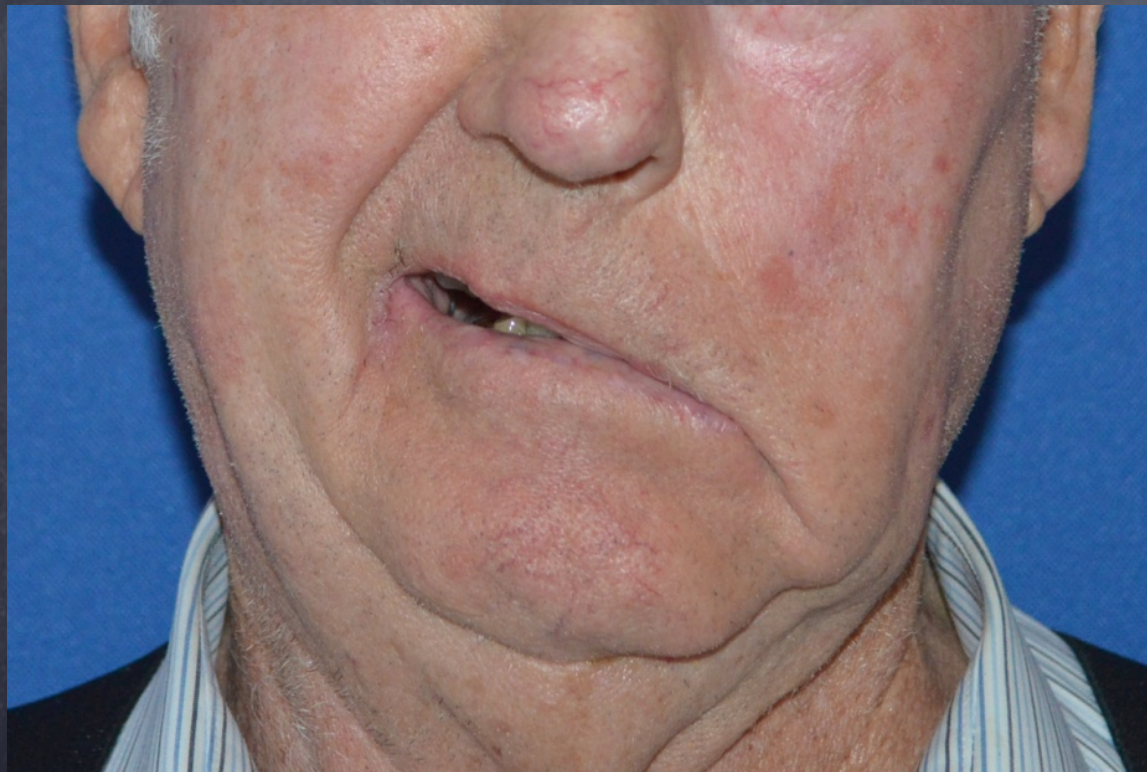# GRACILIS MUSCLE TRANSFER & TEMPORALIS TENDON TRANSFER



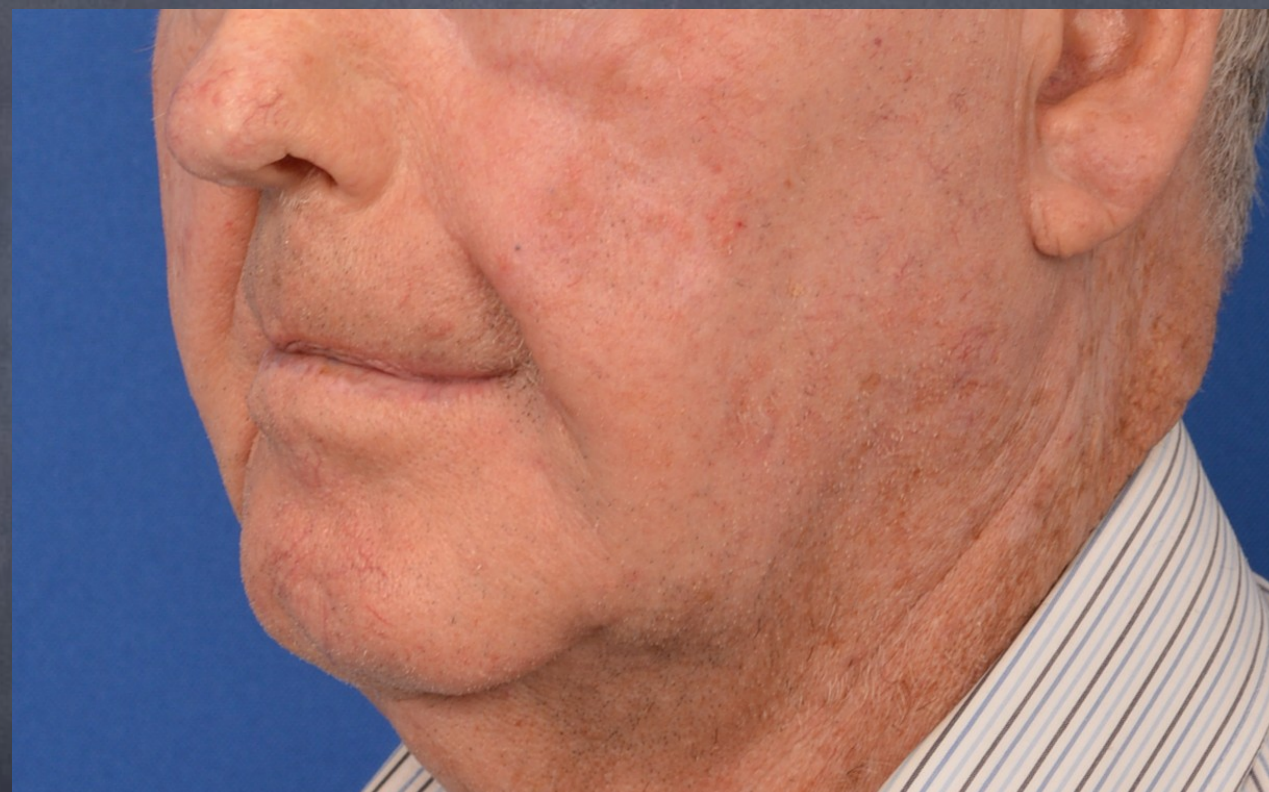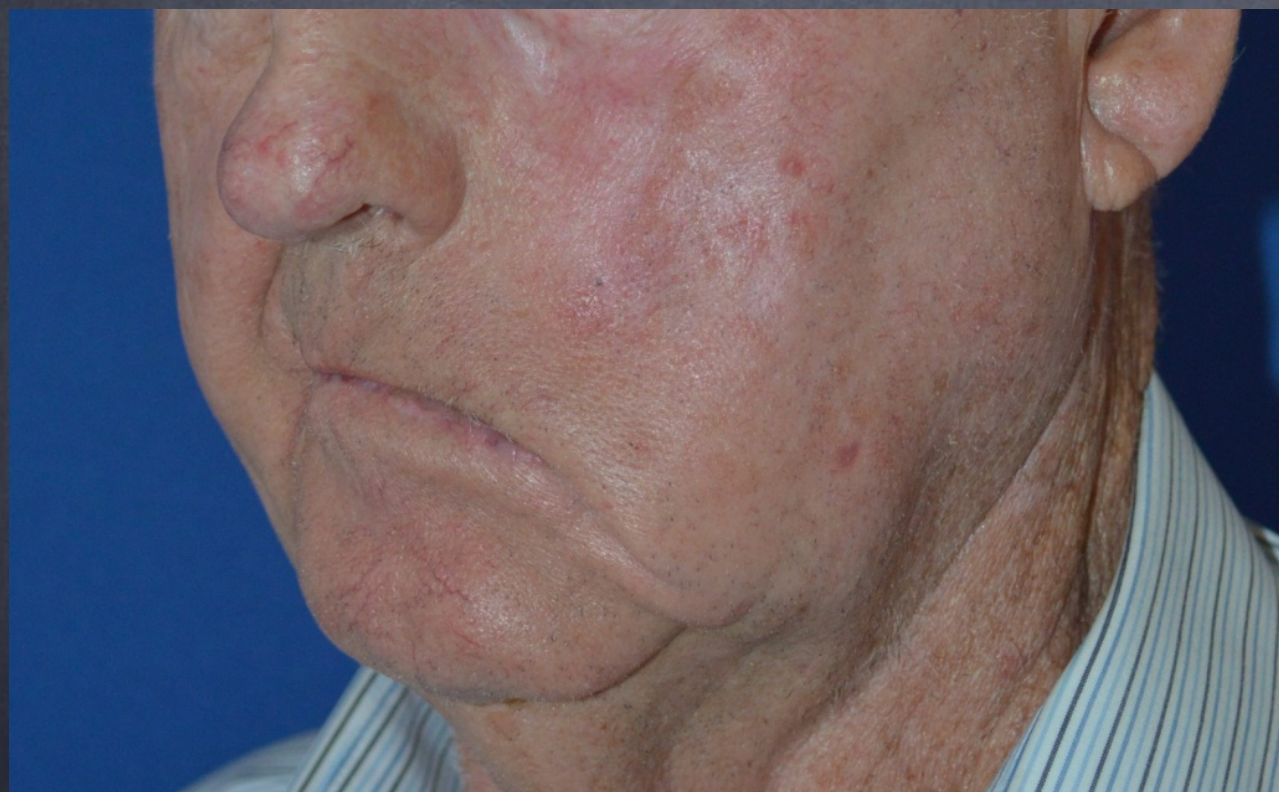Facial Paralysis Institute



# Orthodromic Temporalis Tendon Transfer

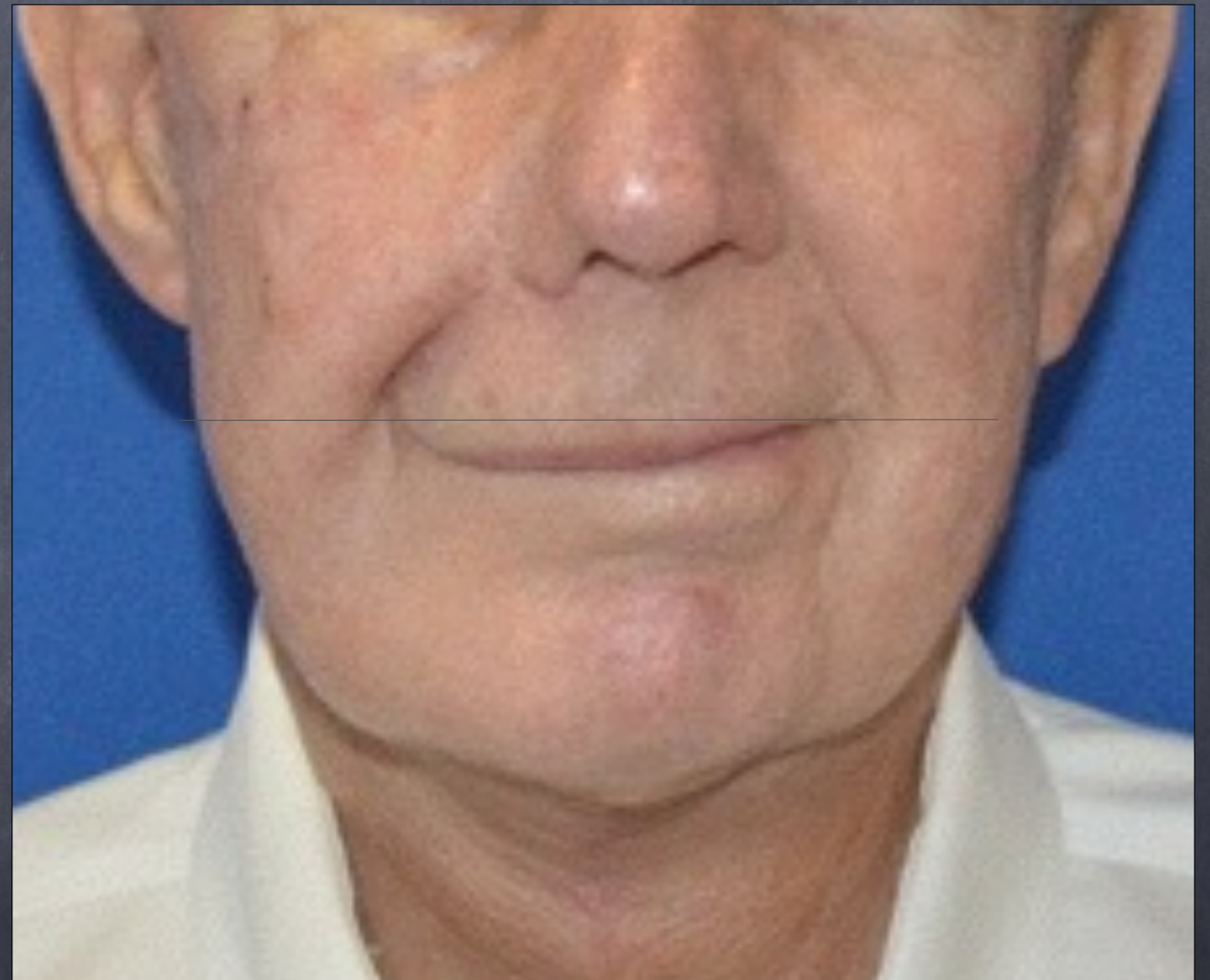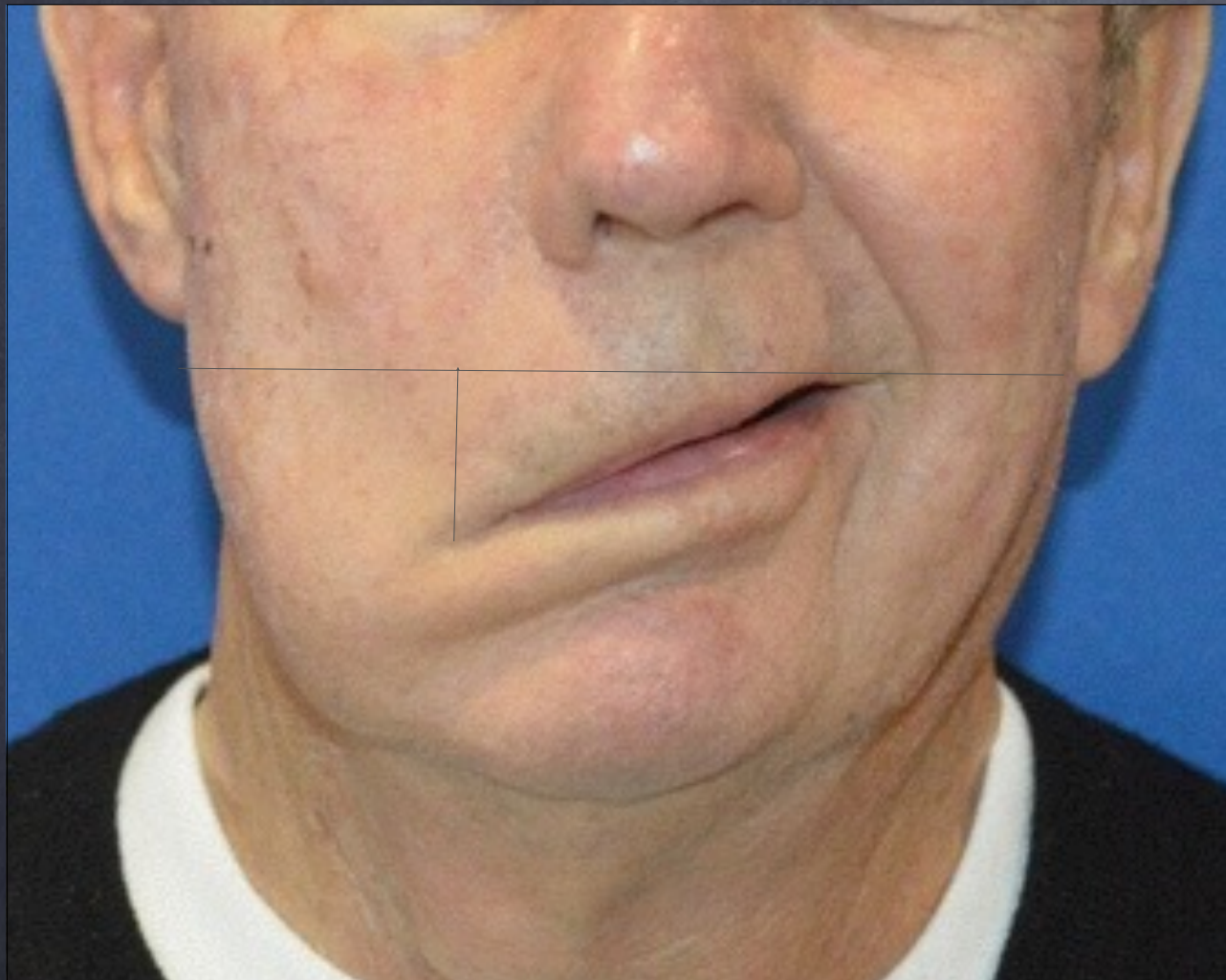







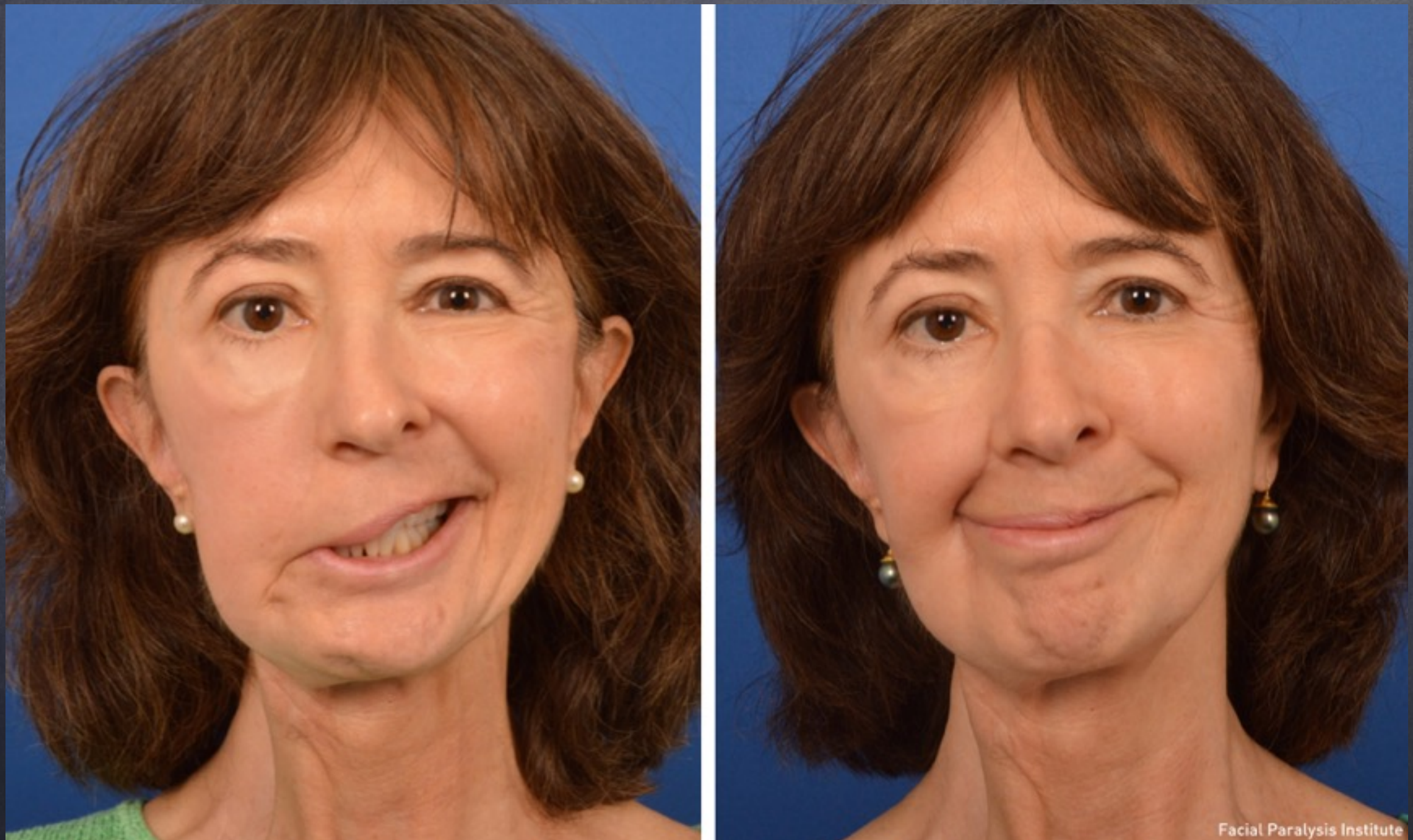
# TEMPORALIS TENDON TRANSFER



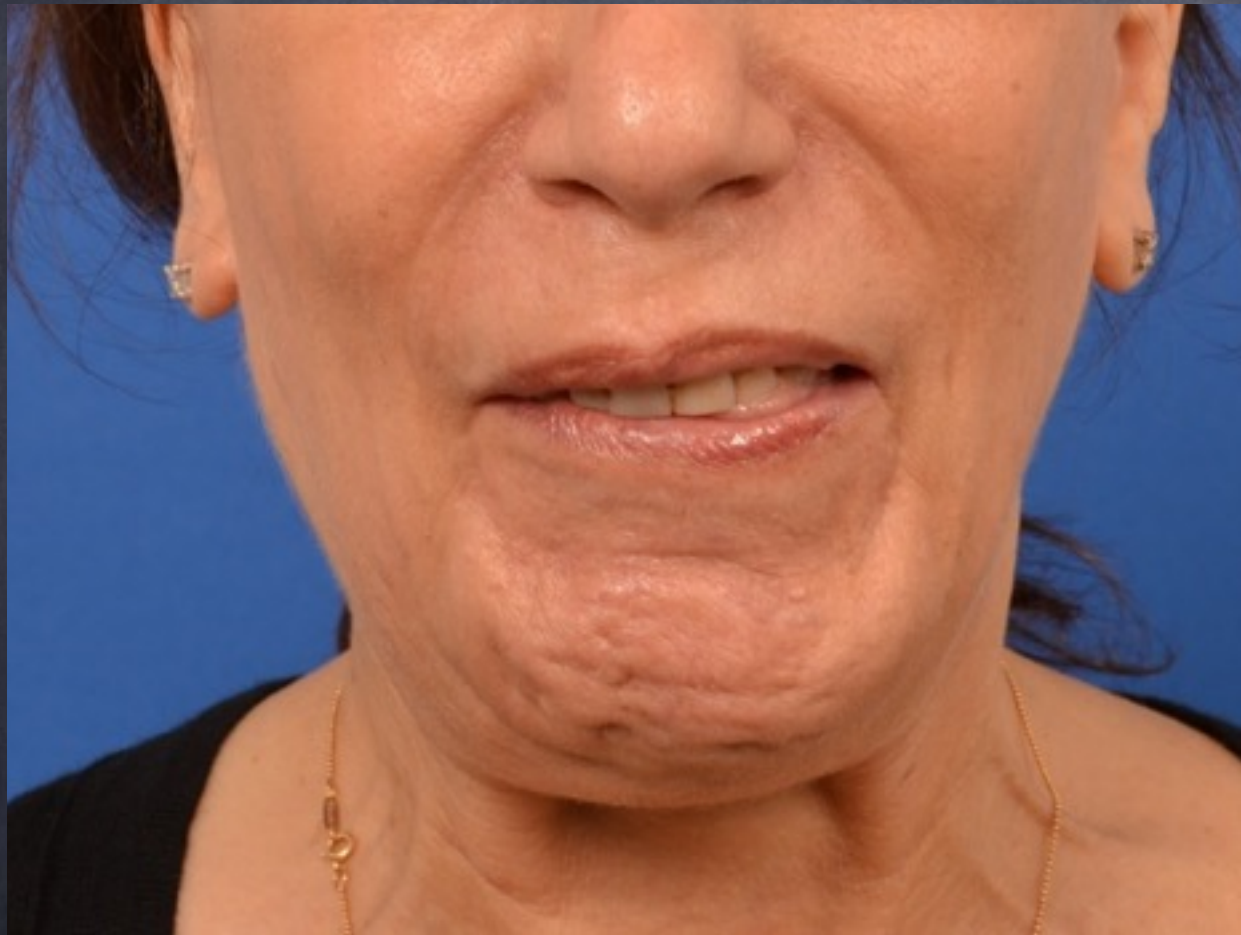

# TEMPORALIS TENDON TRANSFER





# Patient presenting with partial paralysis with synkinesis



- Ophthalmic care as needed depending on severity condition
- Start Neuromuscular retraining as soon as movement returns
- Botox treatments as soon as synkinesis is observed
- Selective neurolysis & rerouting with asymmetric facelift for spontaneous smile reanimation
- NMR, botox, fillers, face/neck lift to optimize outcome
- Other options: Cross face nerve graft with gracilis

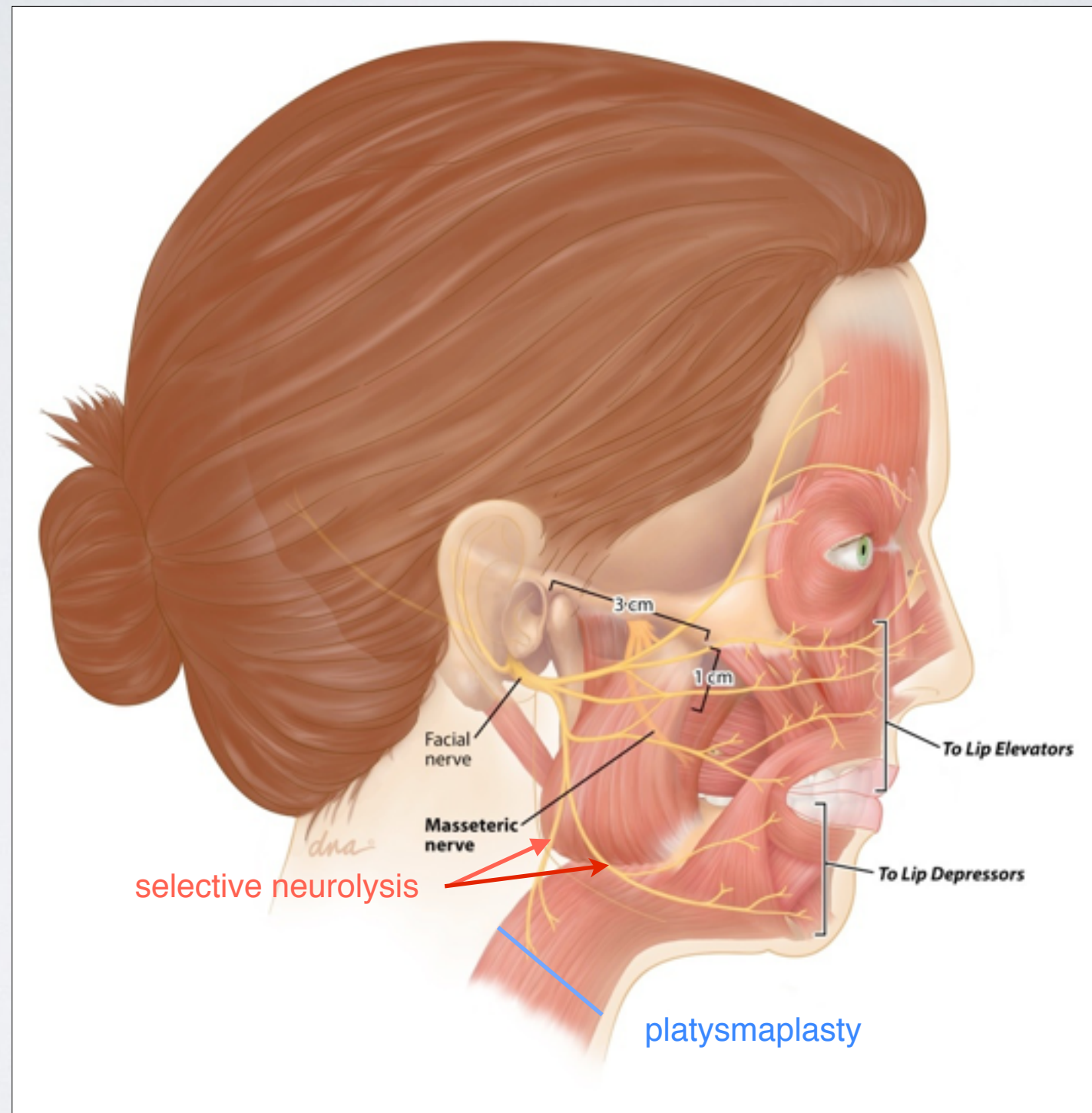


# BOTOX



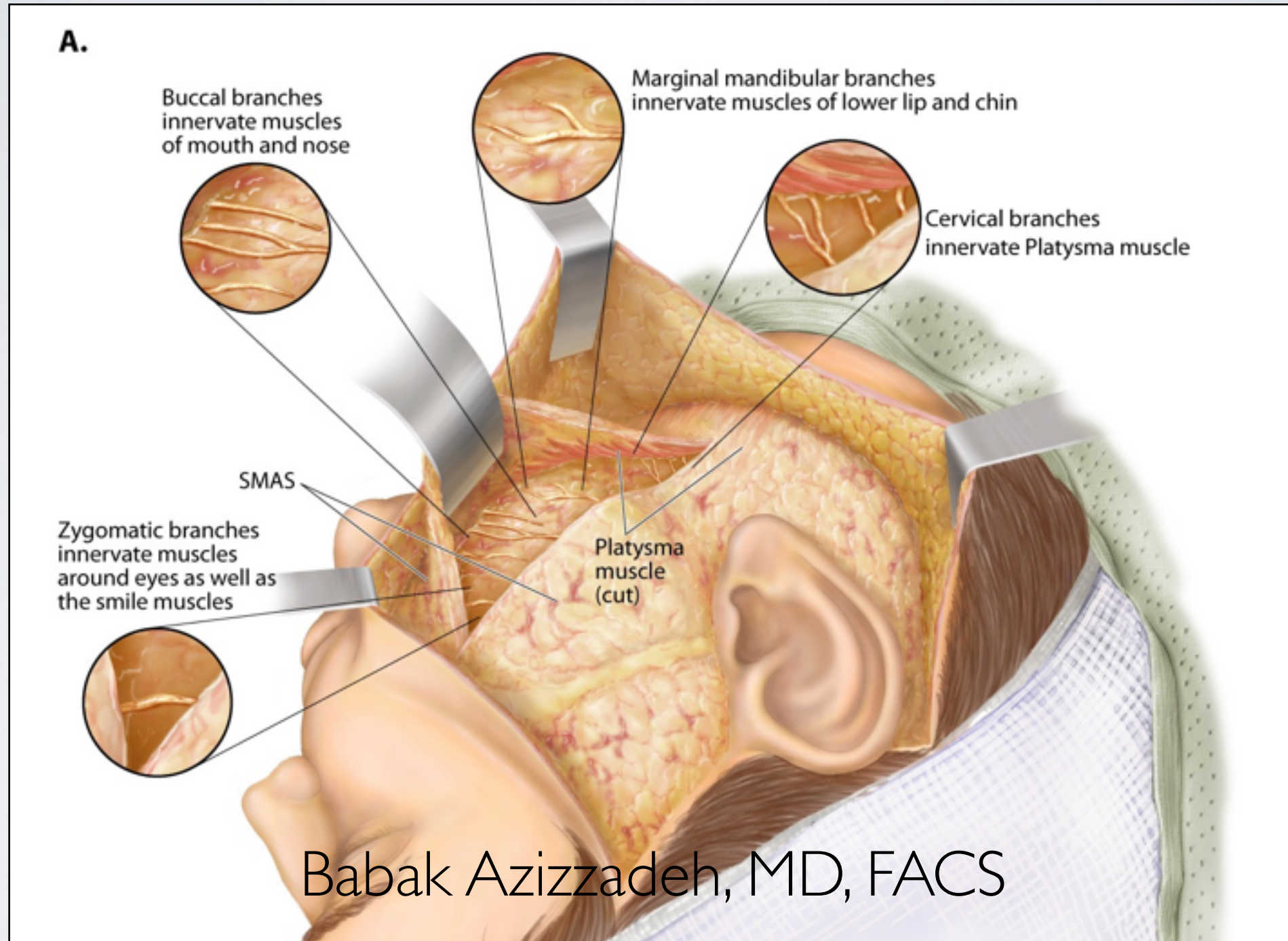


# SELECTIVE NEUROLYSIS WITH PLATYSMAPLASTY



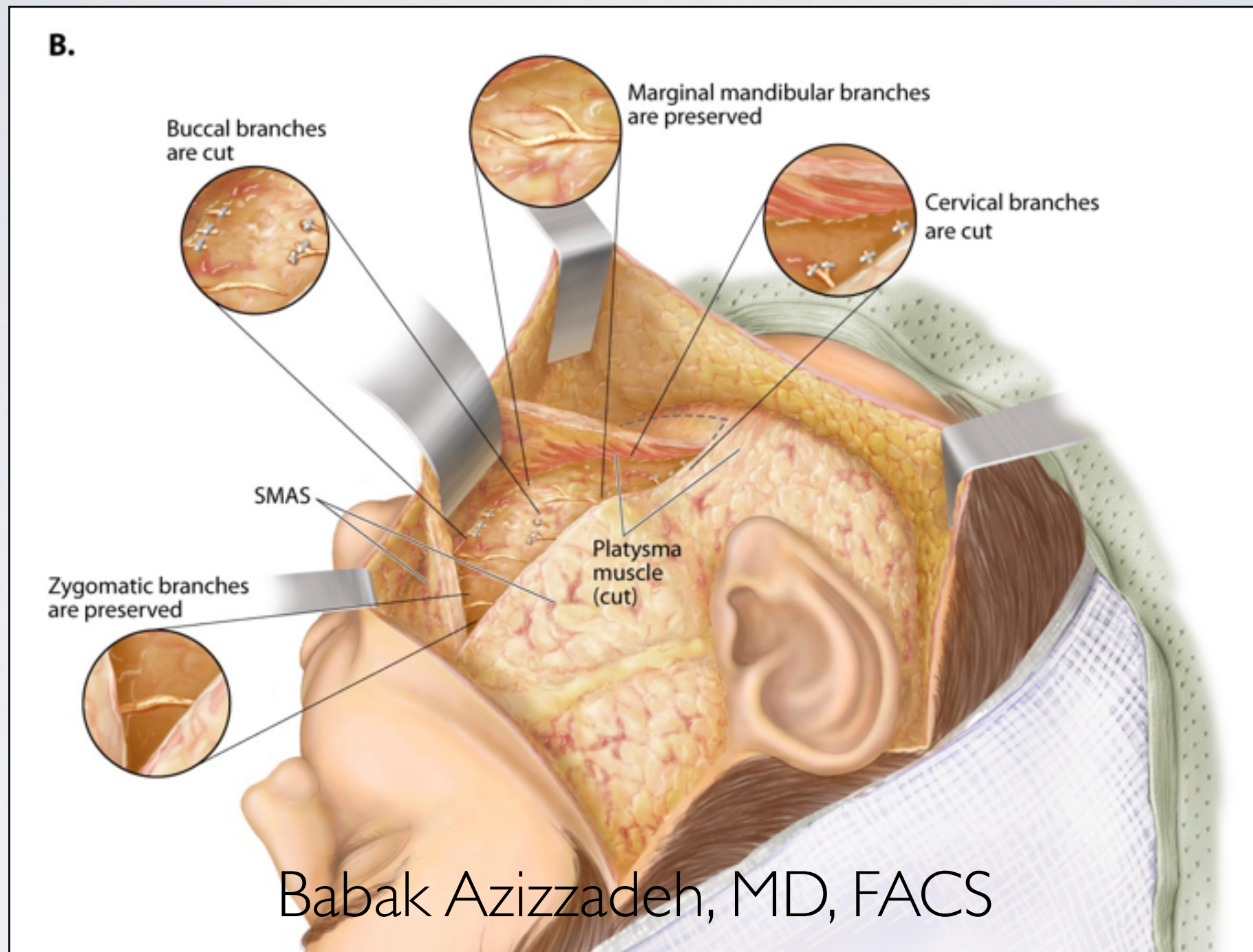


# MAPPING OUT FACIAL NERVES AND INTRAOPERATIVE EMG



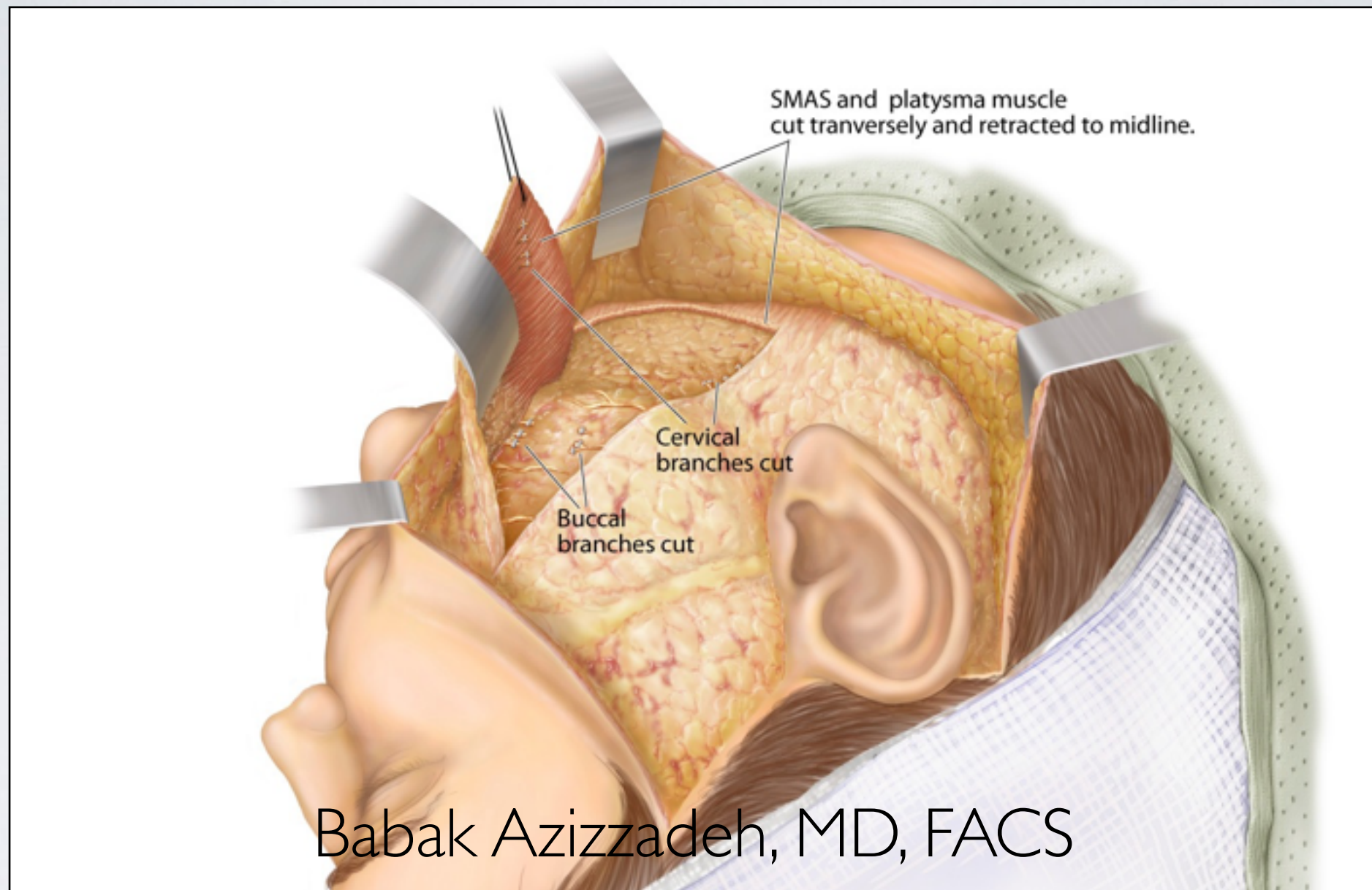


# SELECTIVE NEUROLYSIS



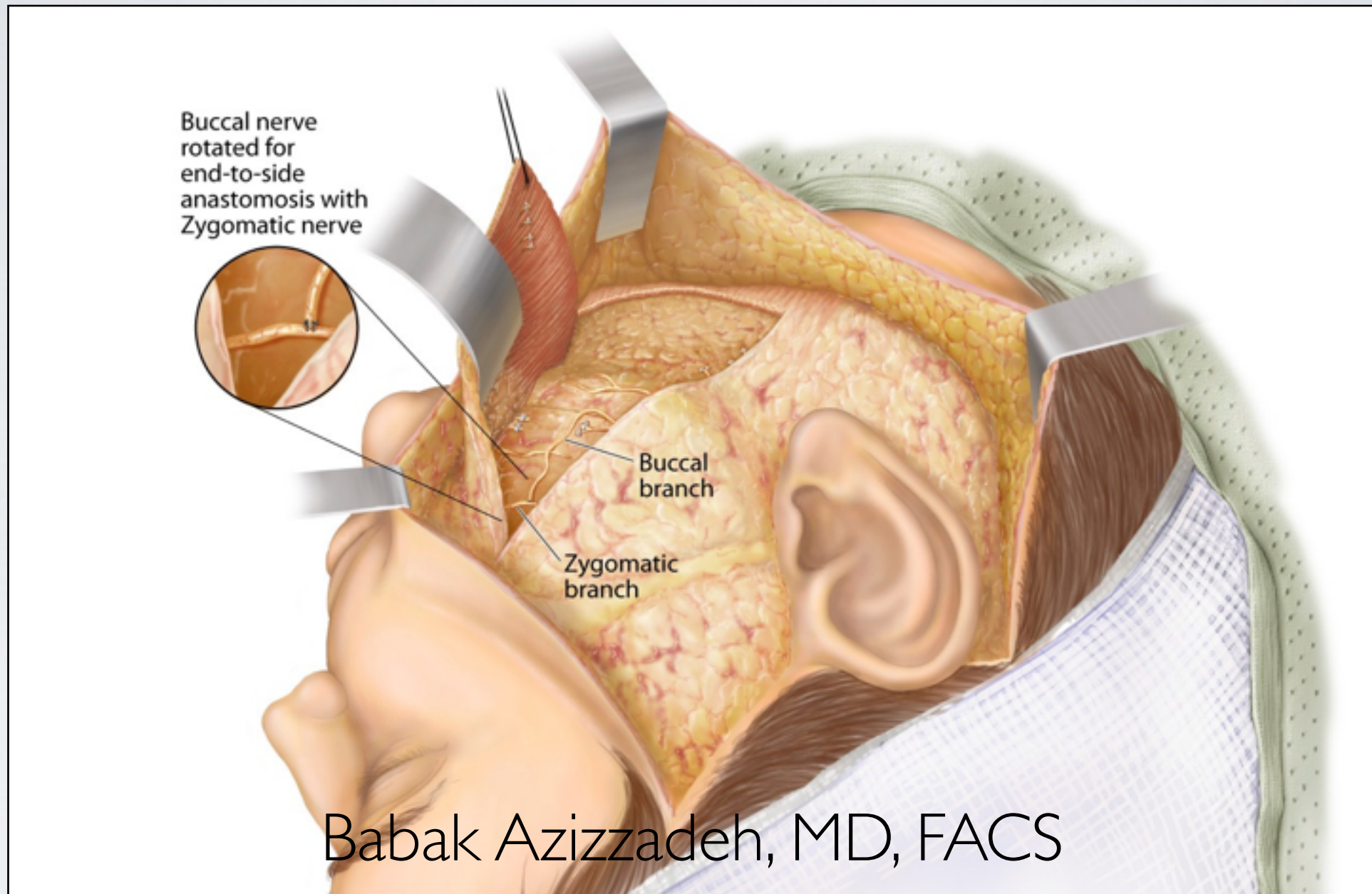


# RELEASE OF PLATYSMA



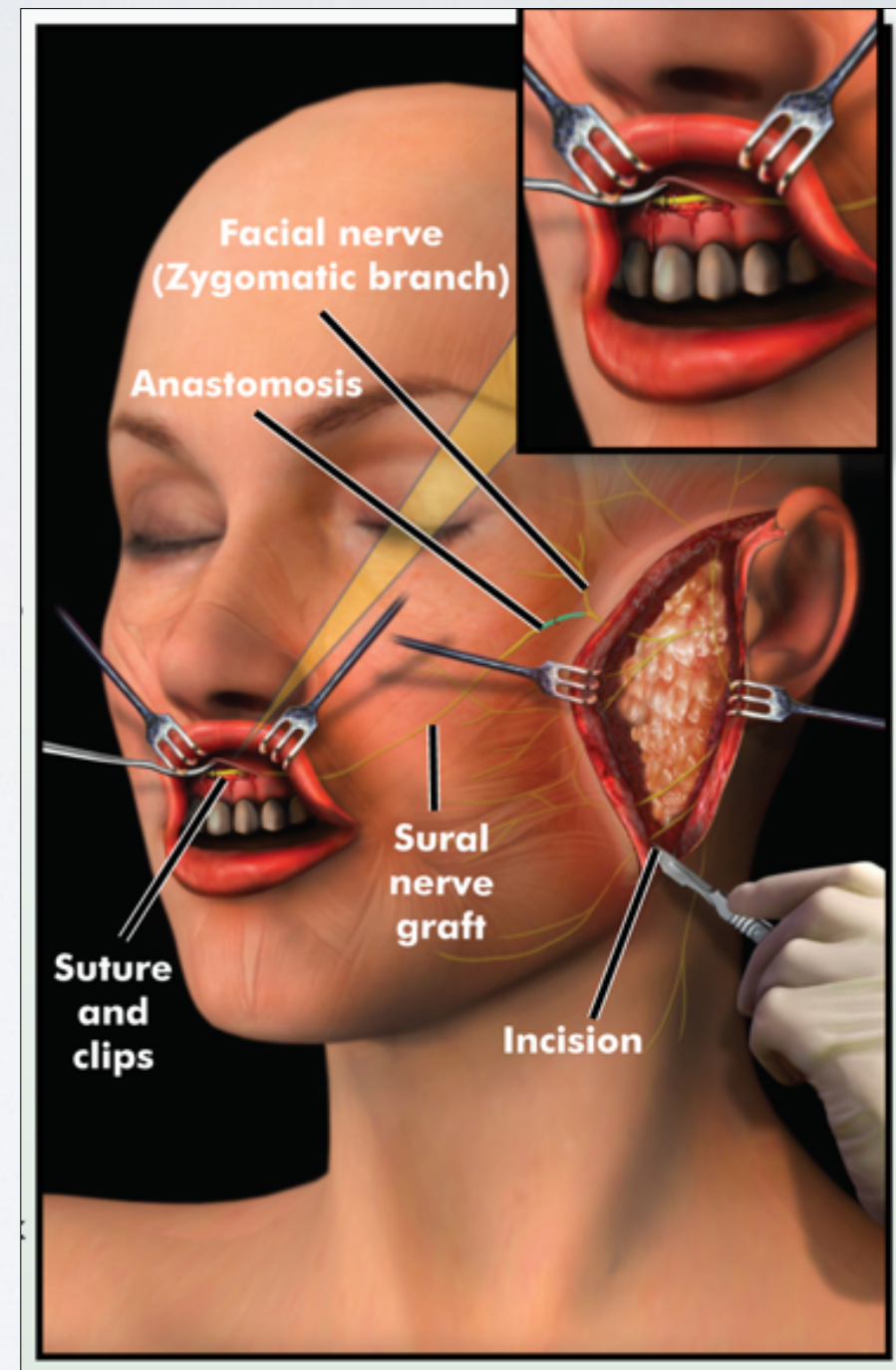
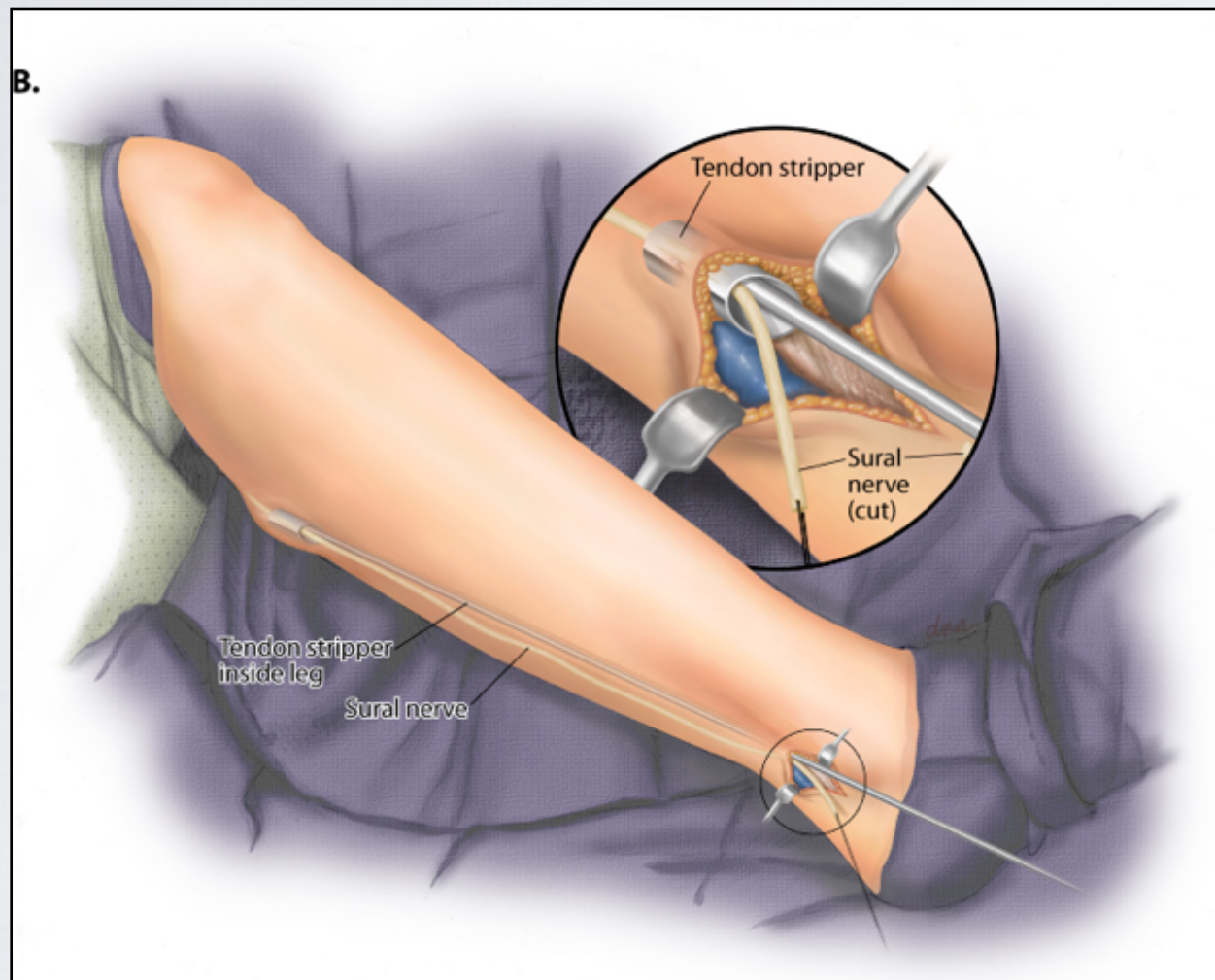


# REROUTING OF BUCCAL BRANCH TO ZYGOMATIC BRANCH TO UPGRADE SIGNAL INTO SMILE MUSCLES



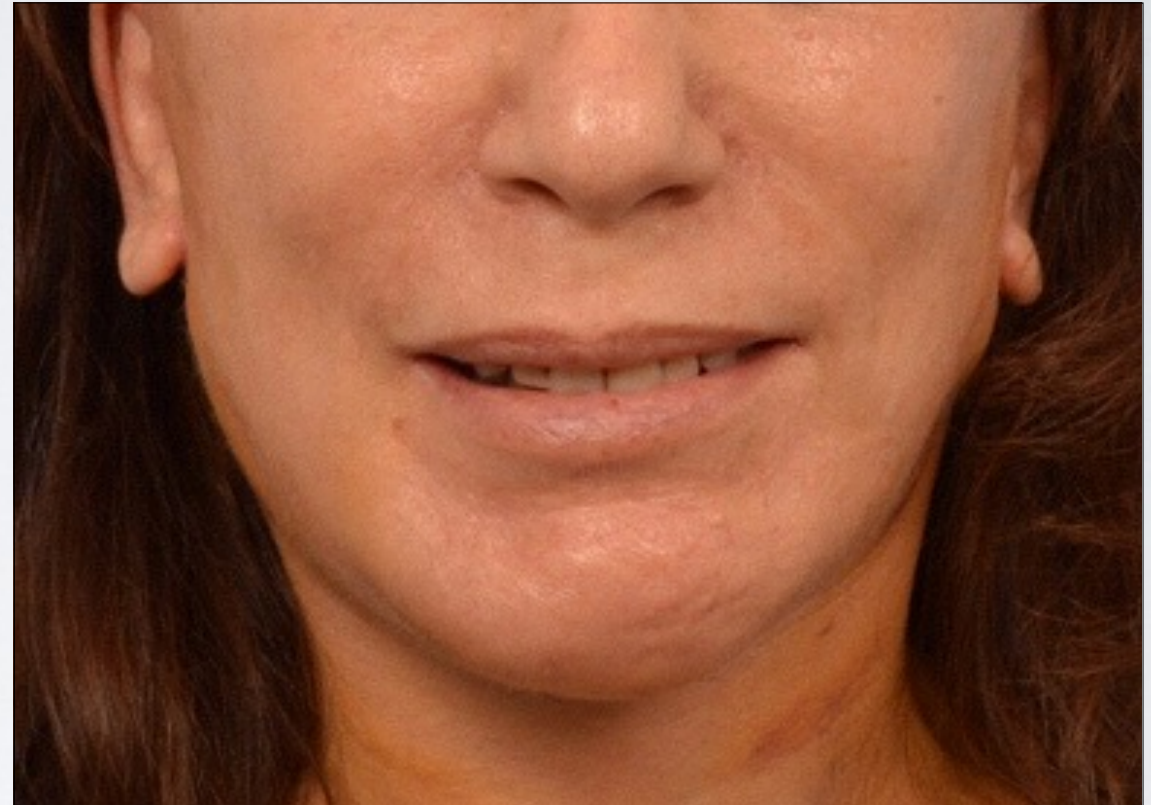
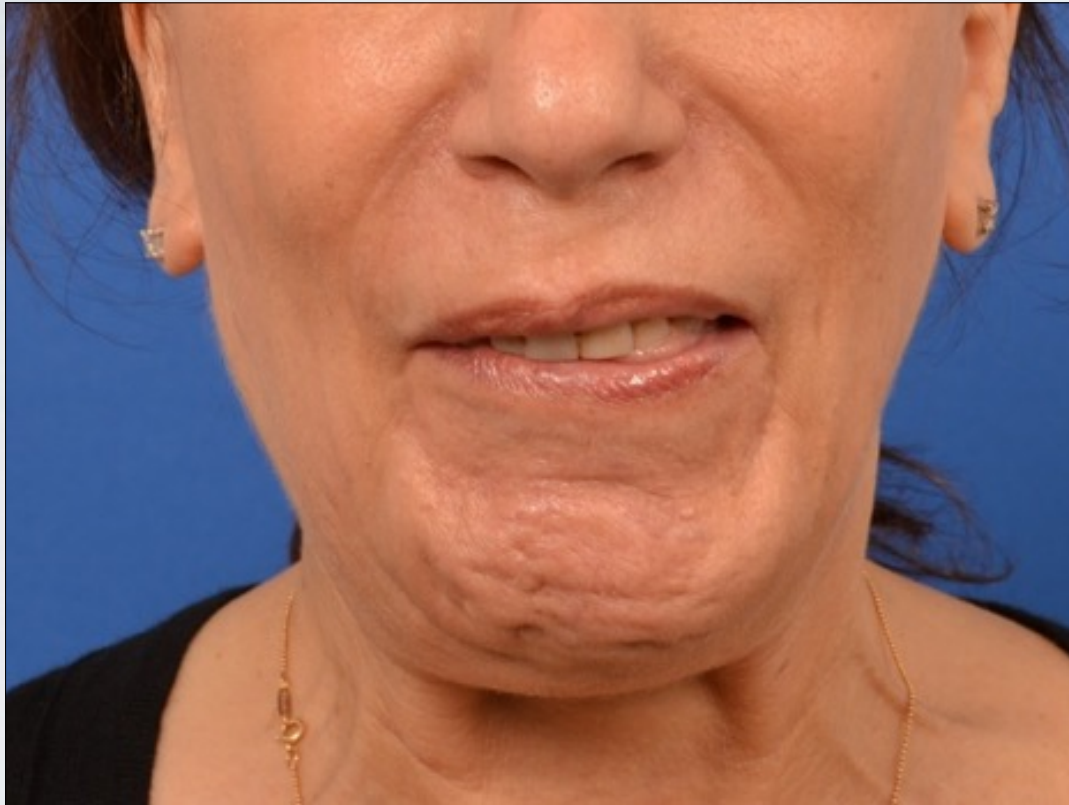
# CROSS FACIAL NERVE GRAFT



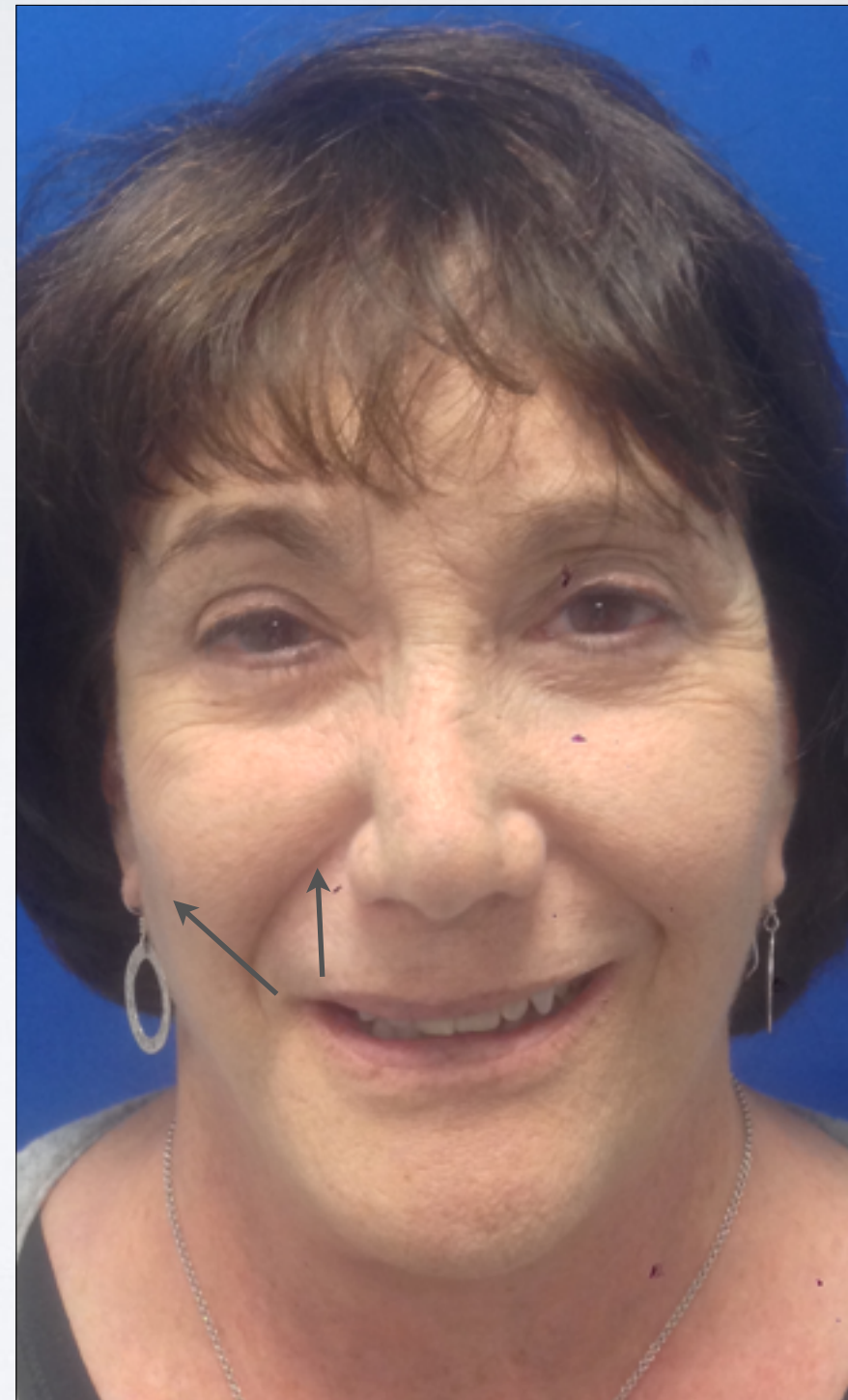


# SELECTIVE NEUROLYSIS; ASYMMETRIC FACE/NECK LIFT





# SELECTIVE NEUROLYSIS; ASYMMETRIC FACE/NECK LIFT



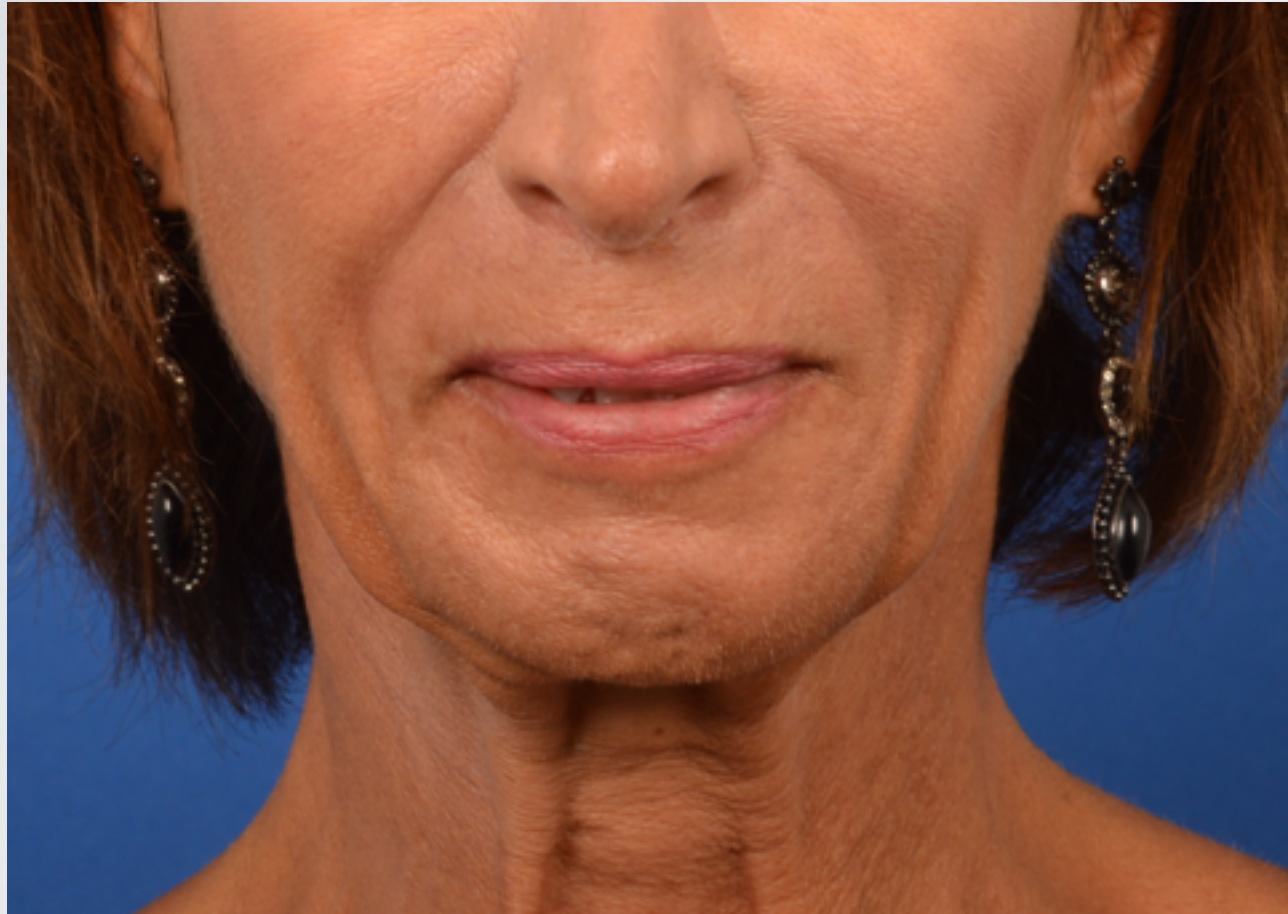

# FACIAL AND EYELID REJUVENATION & SELECTIVE NEUROLYSIS

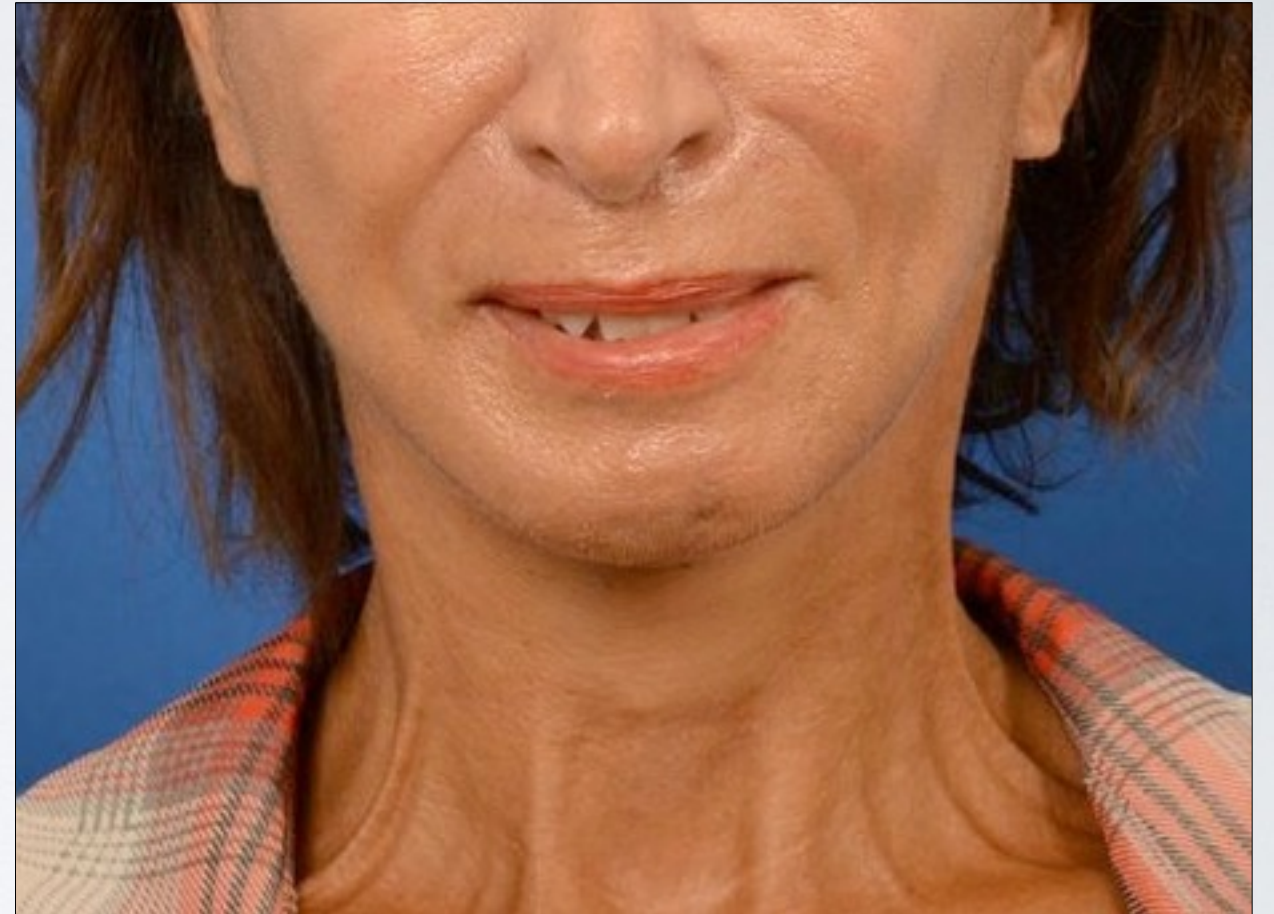



# SELECTIVE NEUROLYSIS FOR BILATERAL PARALYSIS; FACE/NECK LIFT

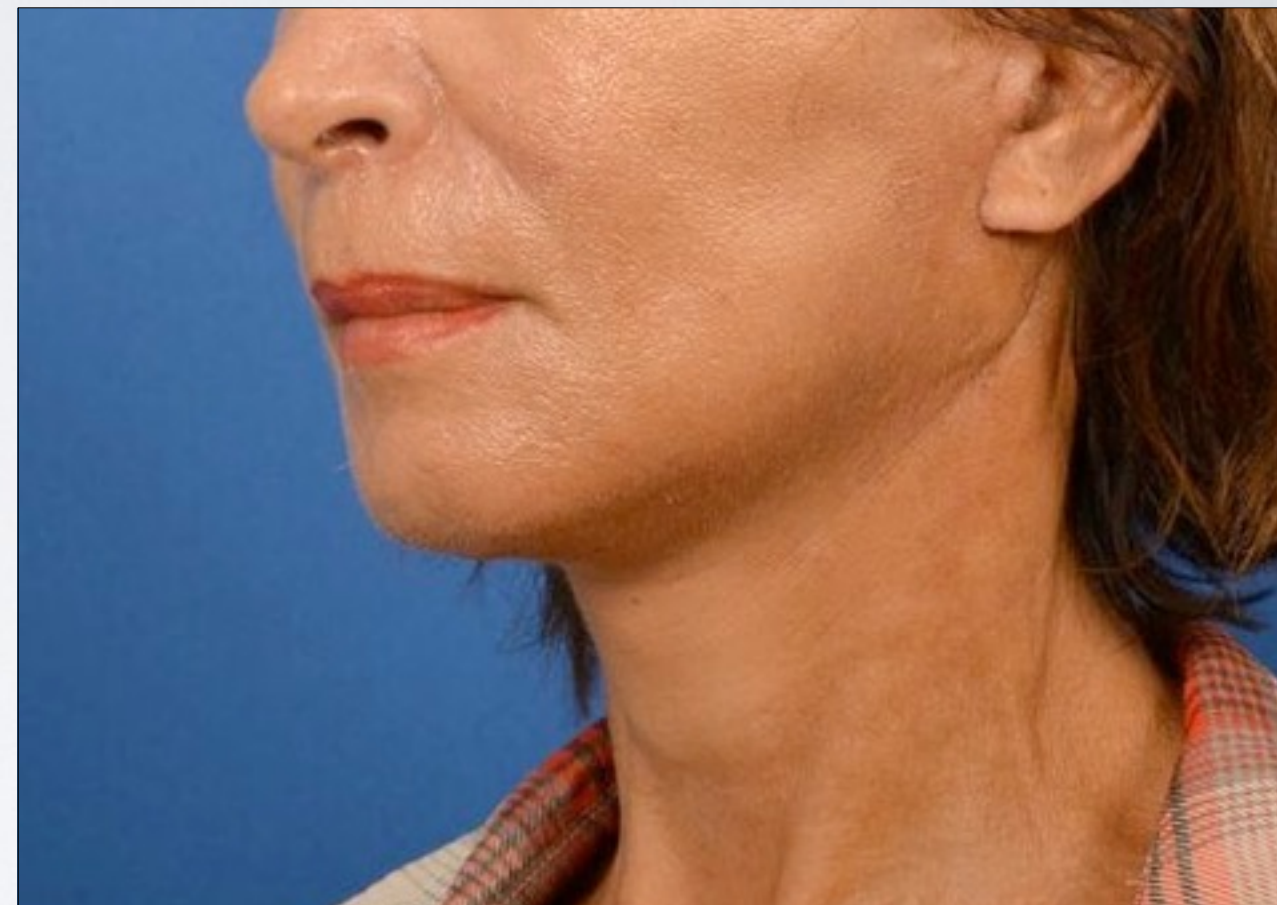
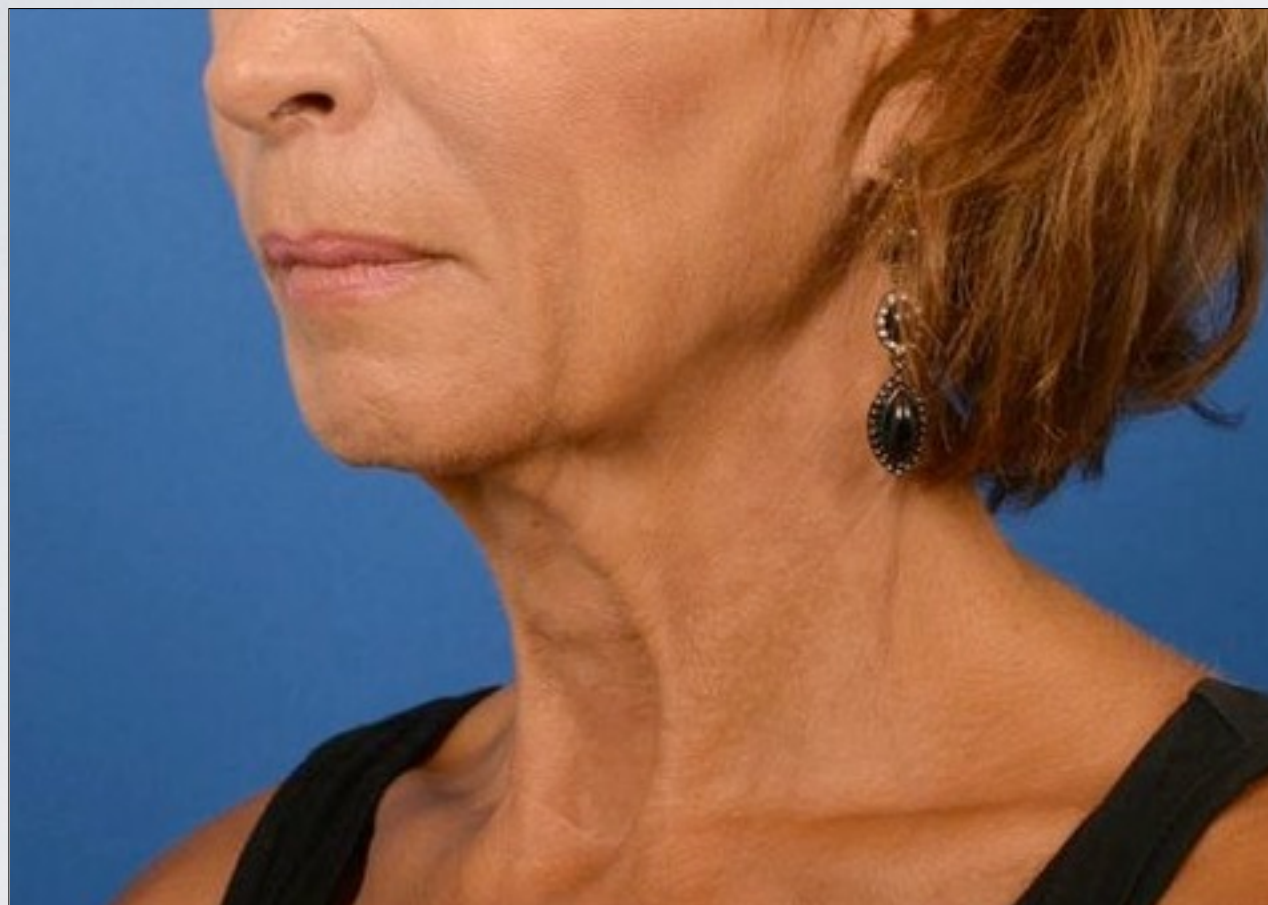
Pre-op Maximal Smile



Post-op Maximal Smile





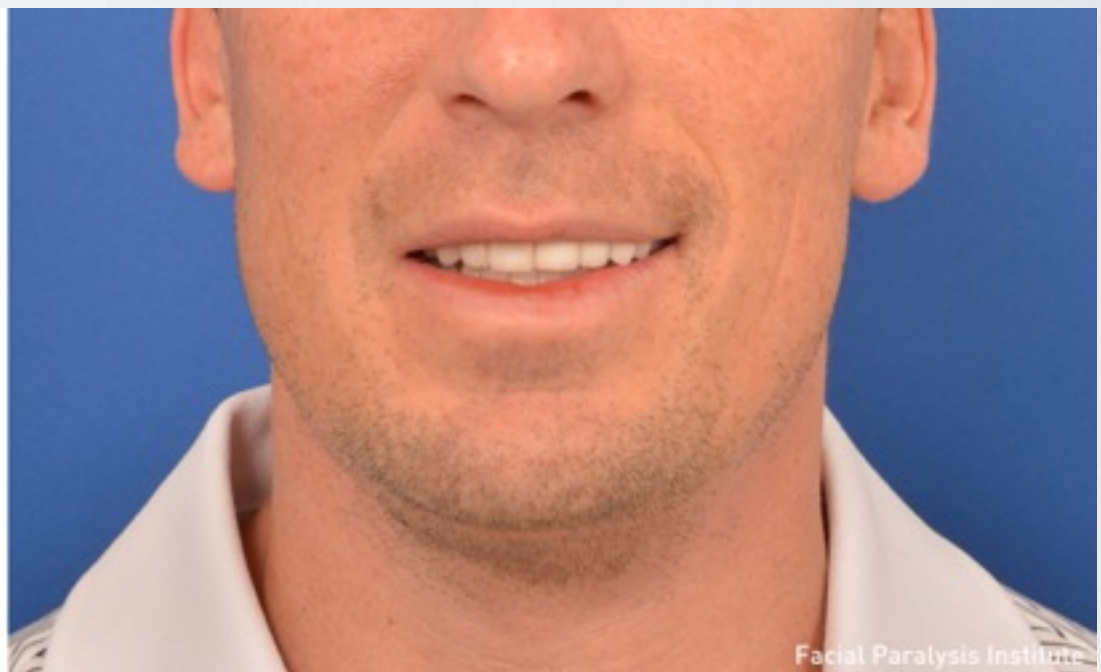

# SELECTIVE NEUROLYSIS



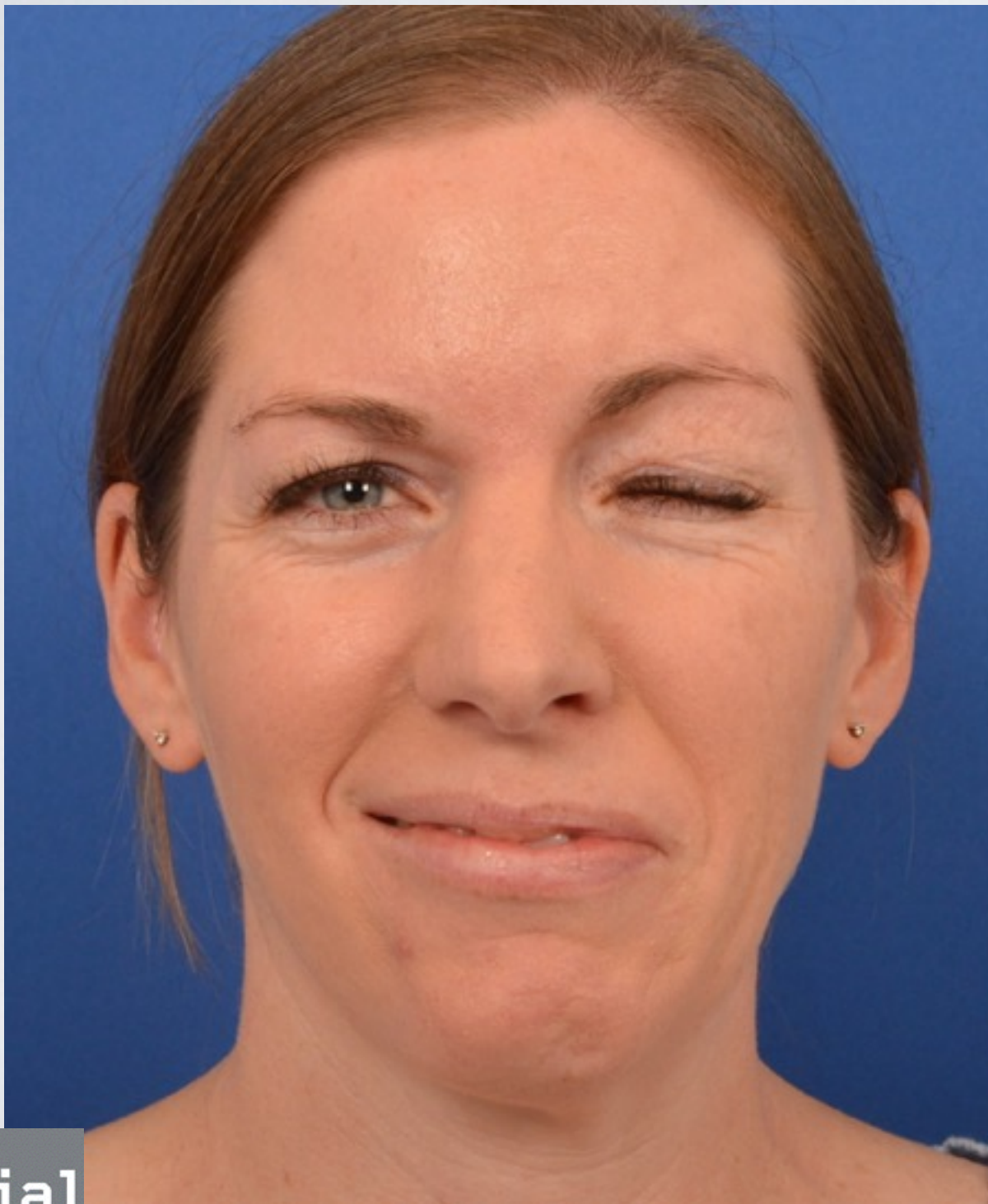

# SELECTIVE NEUROLYSIS



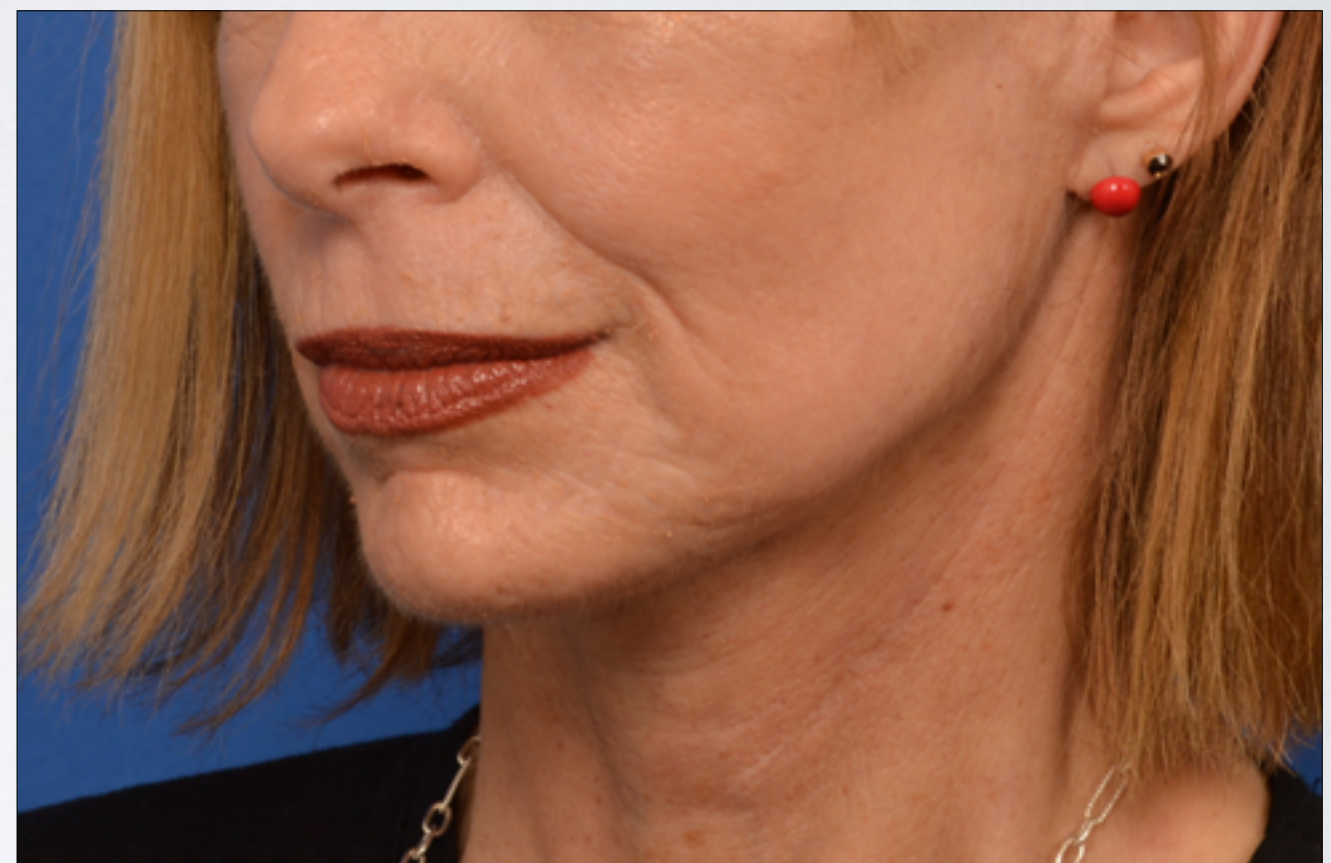
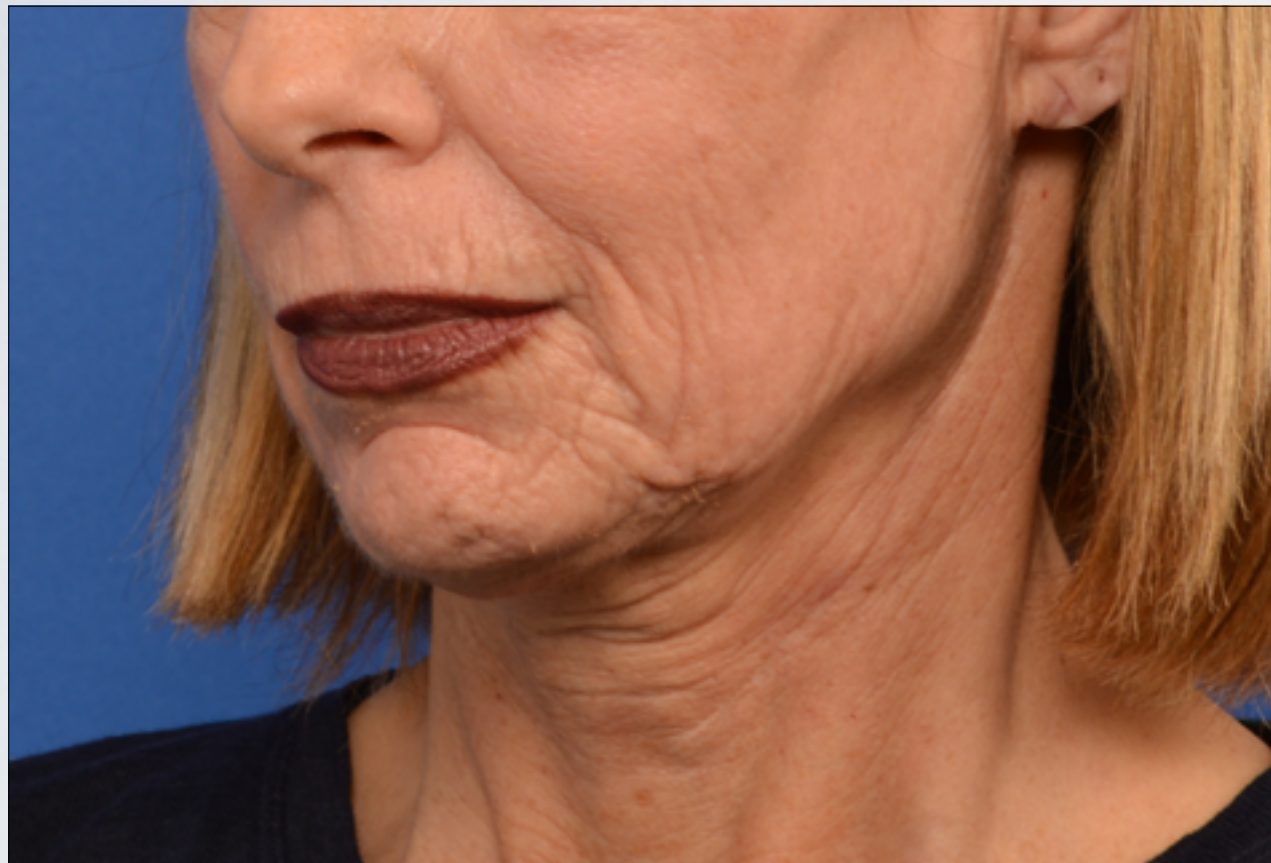
# SELECTIVE NEUROLYSIS & BOTOX

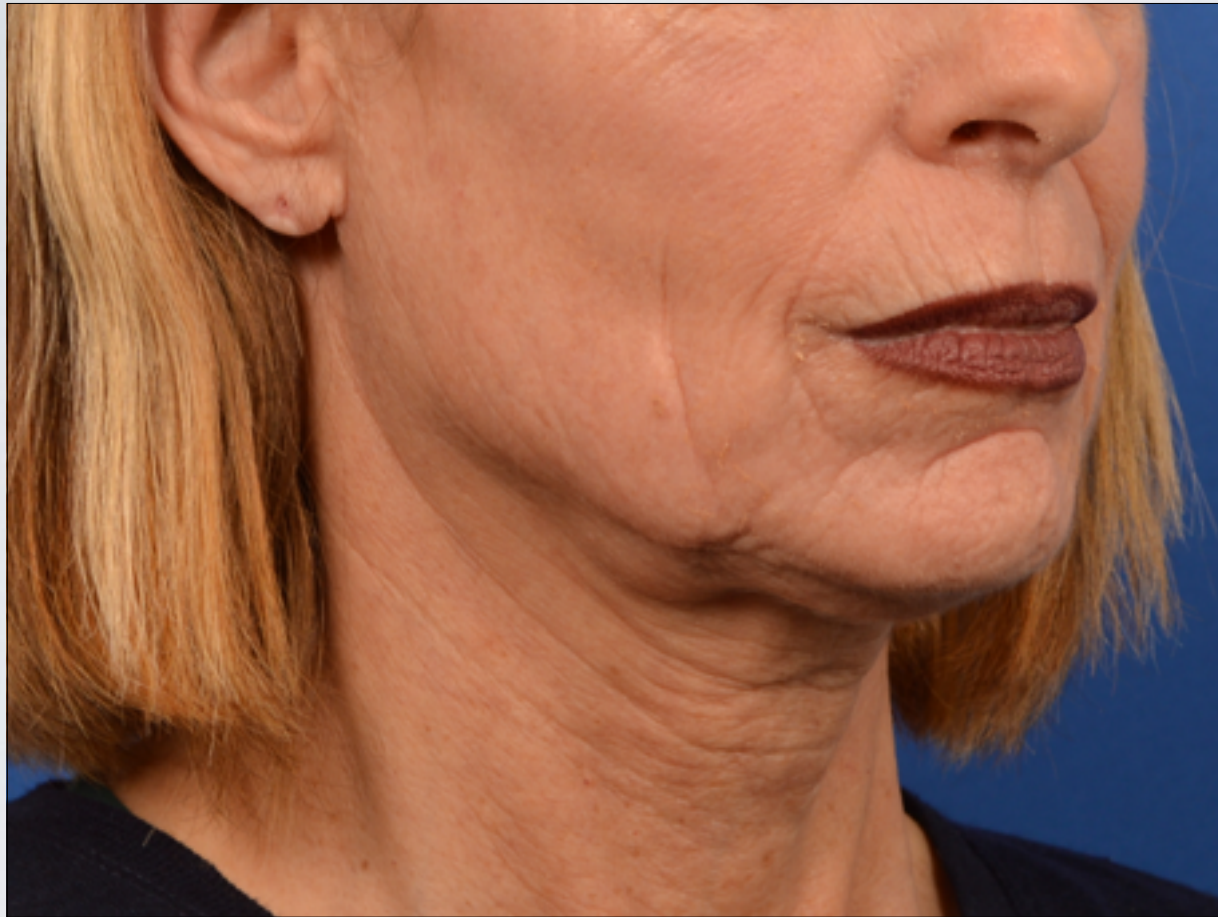




# SELECTIVE NEUROLYSIS & ASYMMETRIC FACE/NECK LIFT









# Conclusions

- FNP is a complex condition and requires a multispecialty approach
- Facial reanimation is NOT PERFECT and cannot truly reproduce a perfect smile; however we have taken significant strides over the past decade
- Reinnervation with hypoglossal or masseteric nerve in appropriate candidates who have total FNP within 18-24 months is crucial to restore muscular tone
- Combining masseteric-facial nerve transfer with cross facial nerve graft & gracilis muscle transfer is treatment of choice for acoustic neuroma patients who have irreversible and complete facial paralysis of less than 18-24 month duration
- Cross face nerve graft and gracilis muscle transfer is treatment of choice for acoustic neuroma patients who have irreversible and complete facial paralysis of more than 24 month duration
- NMR, botox and selective neurolysis improve spontaneous smile mechanism and reduce tightness and tension for acoustic neuroma patients who have persistent synkinesis and partial paralysis; this treatment can be performed at any time past 12 months



# QUESTIONS

- Patient had a 3.2 cm AN removed from right side through suboccipital approach in Nov 2015 and still suffers from facial palsy and inability to blink right eye. The patient was wondering what new treatments or current steps they can take to facilitate healing. The patient is also wondering about the possibility of regaining function
- 30 year post translab patient with facial paralysis, vision loss in left eye (corneal scarring), hearing loss. After having several facial grafts, significant facial droop remains. Three questions: 1. Can facial issues be addressed and improved at this late date? If so, would this require a face lift or . . . .? 2. To pursue improvement options, what type of doctor would be required to consult, a plastic surgeon, or otolaryngologist?
- What might cause eyelid twitching in the AN side for patients that have undergone both surgery and radiation to treat an acoustic neuroma? Is there anything that can be done about it?



# QUESTIONS

- What are reasonable expectations for a patient to have as far as how much improvement they can expect?
- What is recuperation like? Pain level after surgery?
- What are the emotional factors that help people decide whether to have facial surgery, since they have already been through brain surgery?



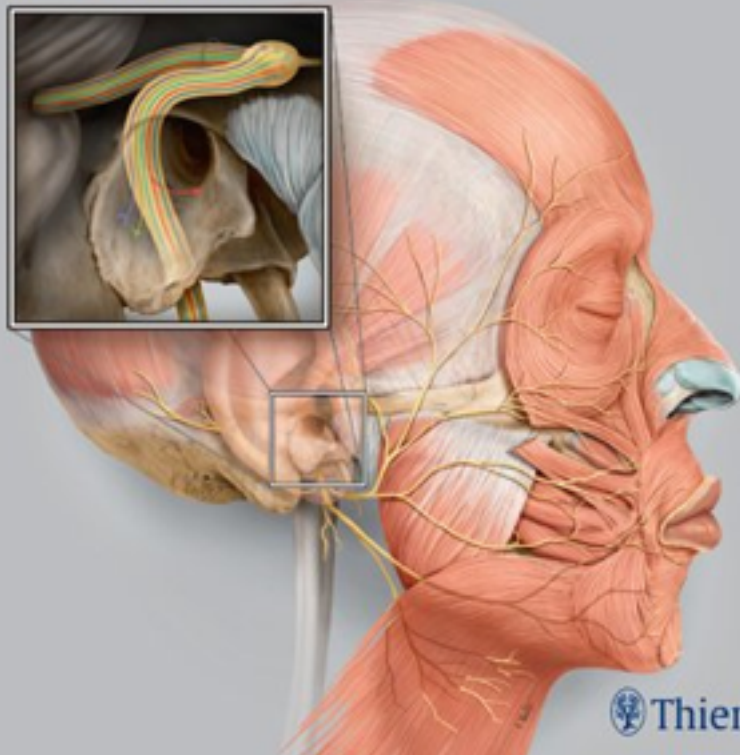
The shortest distance between two  
people is a smile

~Unknown



# The Facial Nerve

William H. Slattery III  
Babak Azizzadeh



## — 13TH — INTERNATIONAL **FACIAL NERVE** SYMPOSIUM

AUGUST 3-6, 2017

*Loews Hollywood Hotel • Los Angeles, CA*

[facialnerve2017@facs.org](mailto:facialnerve2017@facs.org)  
[www.internationalfacialnerve.org](http://www.internationalfacialnerve.org)

Babak Azizzadeh, MD, FACS

[drazizzadeh@gmail.com](mailto:drazizzadeh@gmail.com)





9401 Wilshire Blvd., Suite 650

Beverly Hills, CA 90212

310-657-2203

[info@facialplastics.info](mailto:info@facialplastics.info)

Babak Azizzadeh, MD, FACS